

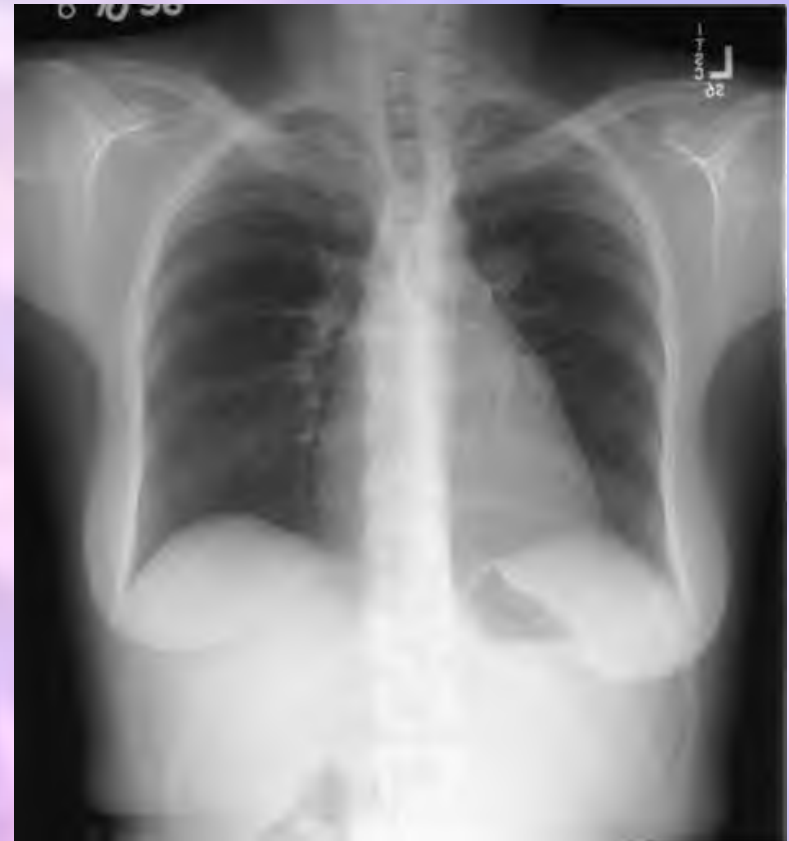**Poltava State
Medical
University,**
Department of
oncology and
radiology
with radiation
medicine
assistant Nestulia K.I.
Lecture 4: Chest
organs.

Introduction

- Routinely obtained
- Pulmonary specialist consultation
- Inherent physical exam limitations
- Chest x-ray limitations
- Physical exam and chest x-ray provide compliment

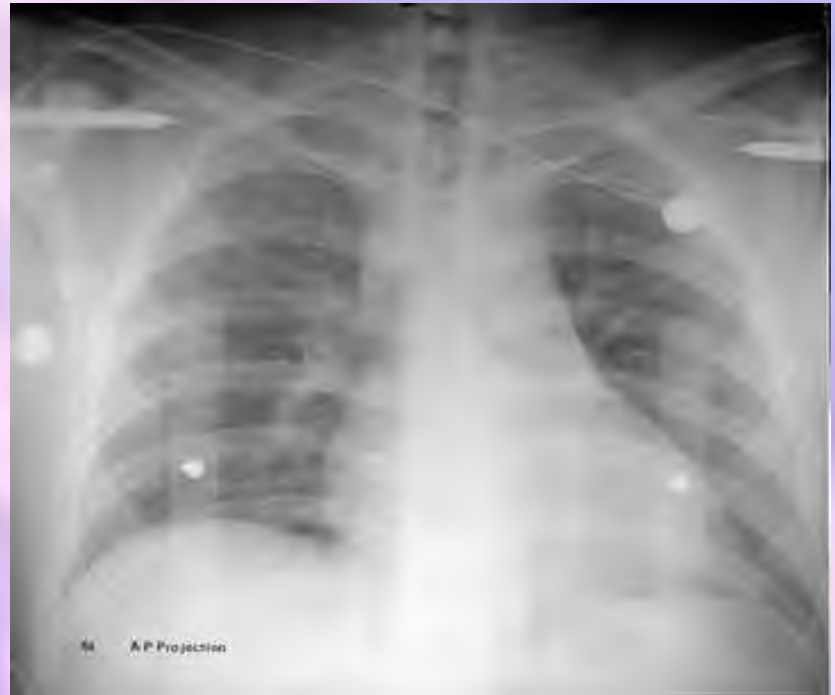Essentials Before Getting Started

- Exposure
 - Overexposure
 - Underexposure
- Sex of Patient
 - Male
 - Female



Essentials Before Getting Started

- Path of x-ray beam
 - PA
 - AP
- Patient Position
 - Upright
 - Supine



Essentials Before Getting Started

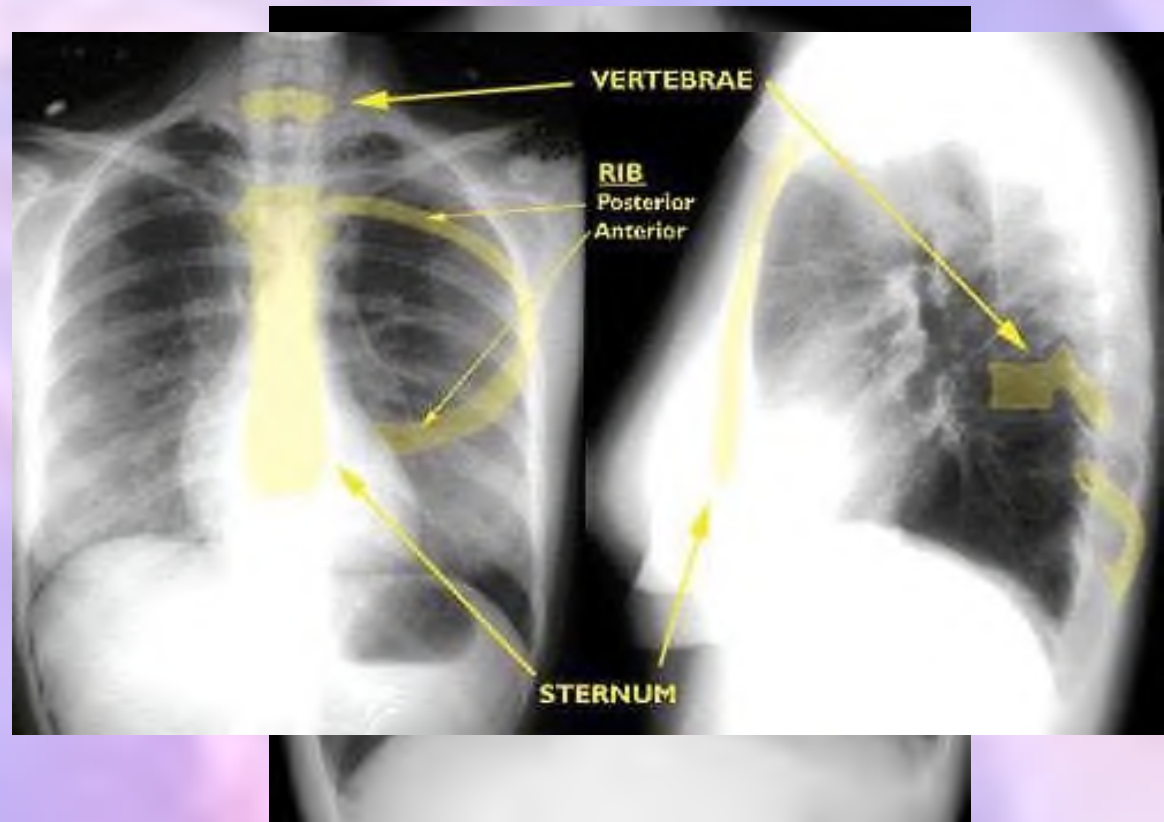
- Breath
 - Inspiration
 - Expiration

Systematic Approach

- Bony Framework
- Soft Tissues
- Lung Fields and Hila
- Diaphragm and Pleural Spaces
- Mediastinum and Heart
- Abdomen and Neck

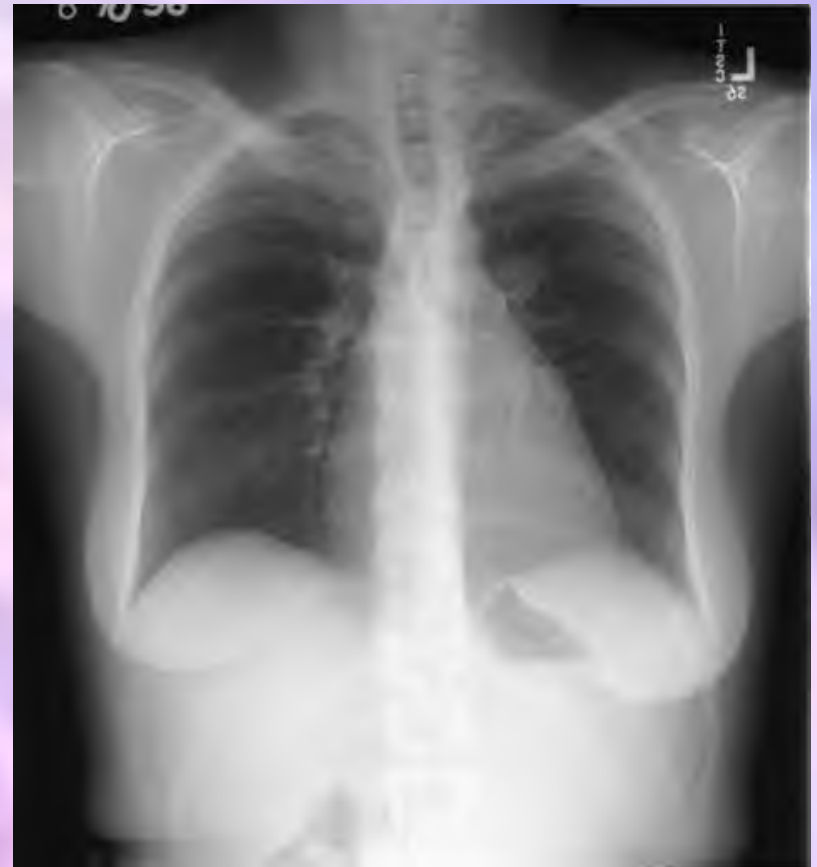Systematic Approach

- Bony Fragments
 - Ribs
 - Sternum
 - Spine
 - Shoulder girdle
 - Clavicles



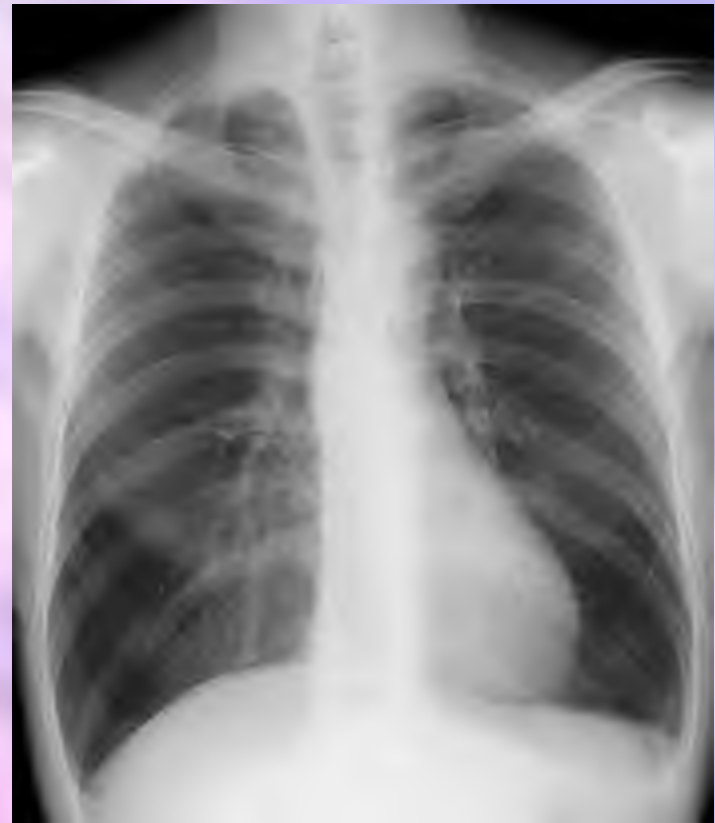Systematic Approach

- Soft Tissues
 - Breast shadows
 - Supraclavicular areas
 - Axillae
 - Tissues along side of breasts



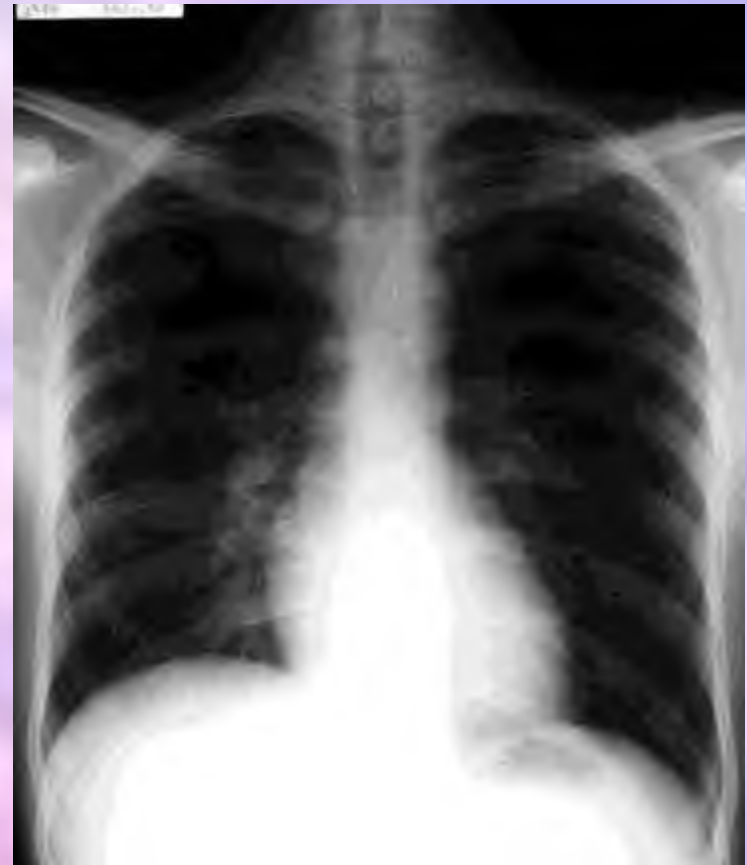Systematic Approach

- Lung Fields and Hila
 - Hilum
 - Pulmonary arteries
 - Pulmonary veins
 - Lungs
 - Linear and fine nodular shadows of pulmonary vessels
 - Blood vessels
 - 40% obscured by other tissue



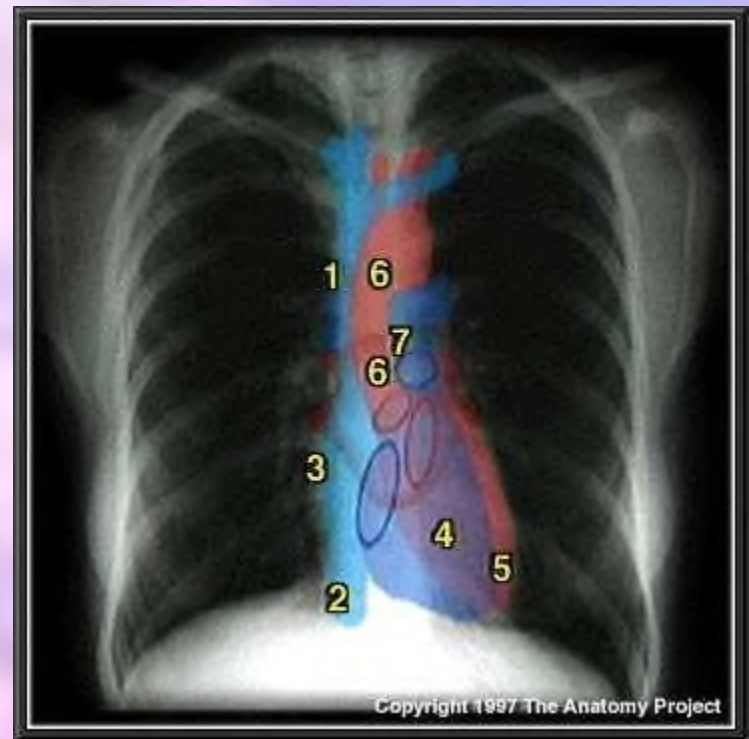
Systematic Approach

- Diaphragm and Pleural Surfaces
 - Diaphragm
 - Dome-shaped
 - Costophrenic angles
 - Normal pleural is not visible
 - Interlobar fissures



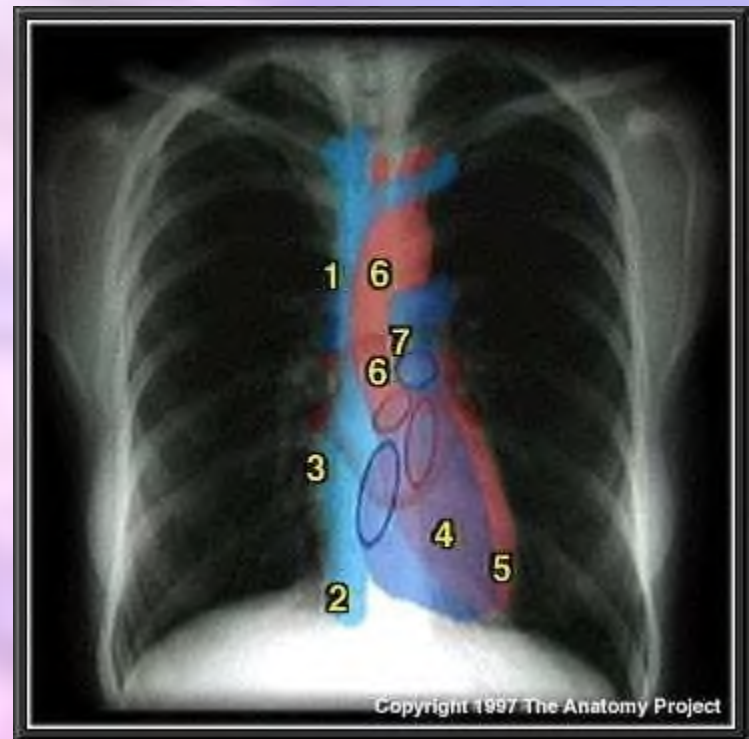
Systematic Approach

- Mediastinum and Heart
 - Heart size on PA
 - Right side
 - Inferior vena cava
 - Right atrium
 - Ascending aorta
 - Superior vena cava



Systematic Approach

- Mediastinum and Heart
 - Left side
 - Left ventricle
 - Left atrium
 - Pulmonary artery
 - Aortic arch
 - Subclavian artery and vein



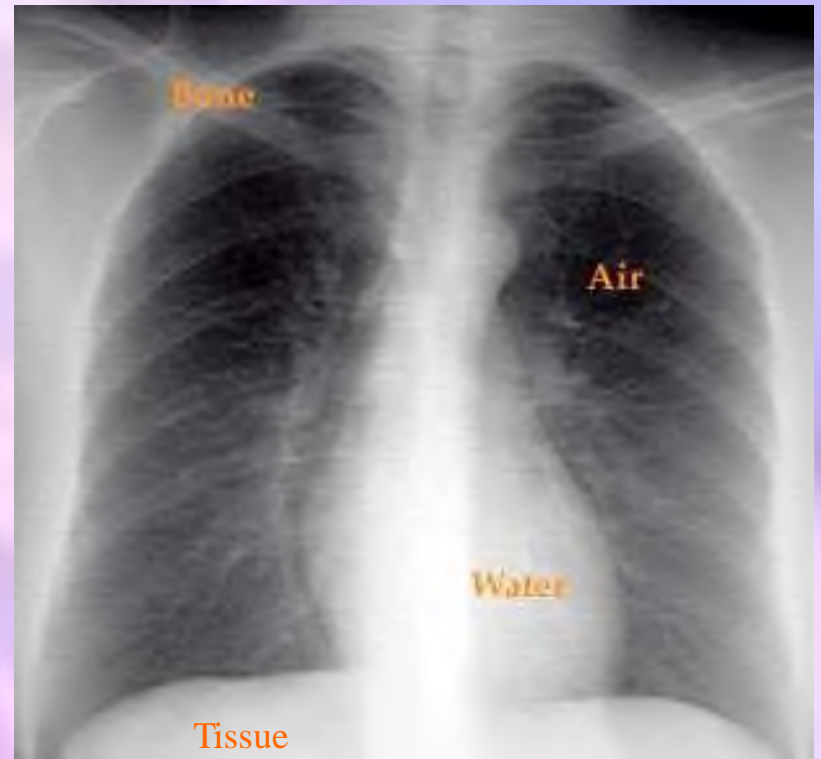
Systematic Approach

- Abdomen and Neck
 - Abdomen
 - Gastric bubble
 - Air under diaphragm
 - Neck
 - Soft tissue mass
 - Air bronchogram



Summary of Density

- Air
- Water
- Bone
- Tissue

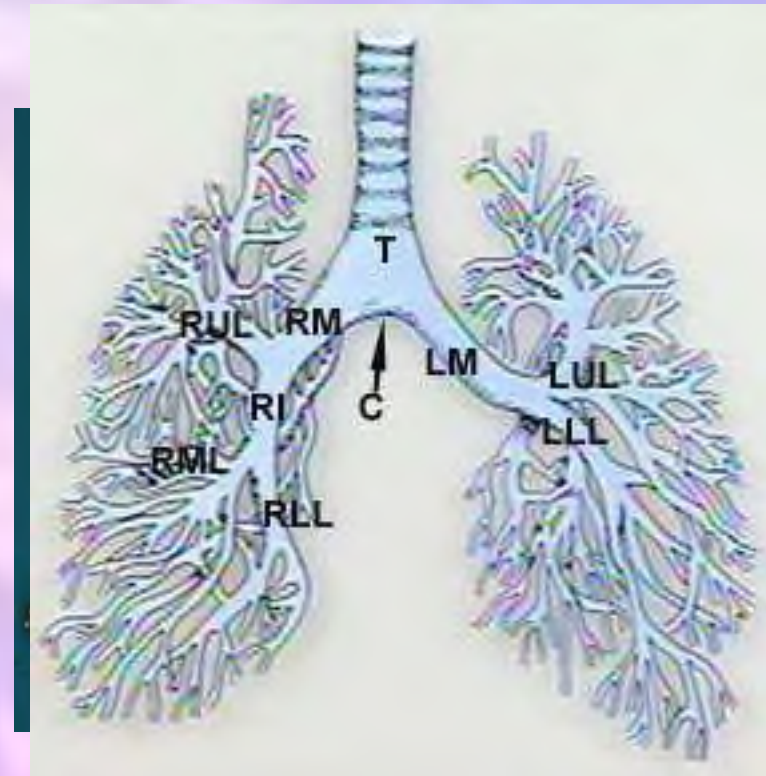


Pitfalls to Chest X-ray Interpretation

- Poor inspiration
- Over or under penetration
- Rotation
- Forgetting the path of the x-ray beam

Lung Anatomy

- Trachea
- Carina
- Right and Left Pulmonary Bronchi
- Secondary Bronchi
- Tertiary Bronchi
- Bronchioles
- Alveolar Duct
- Alveoli



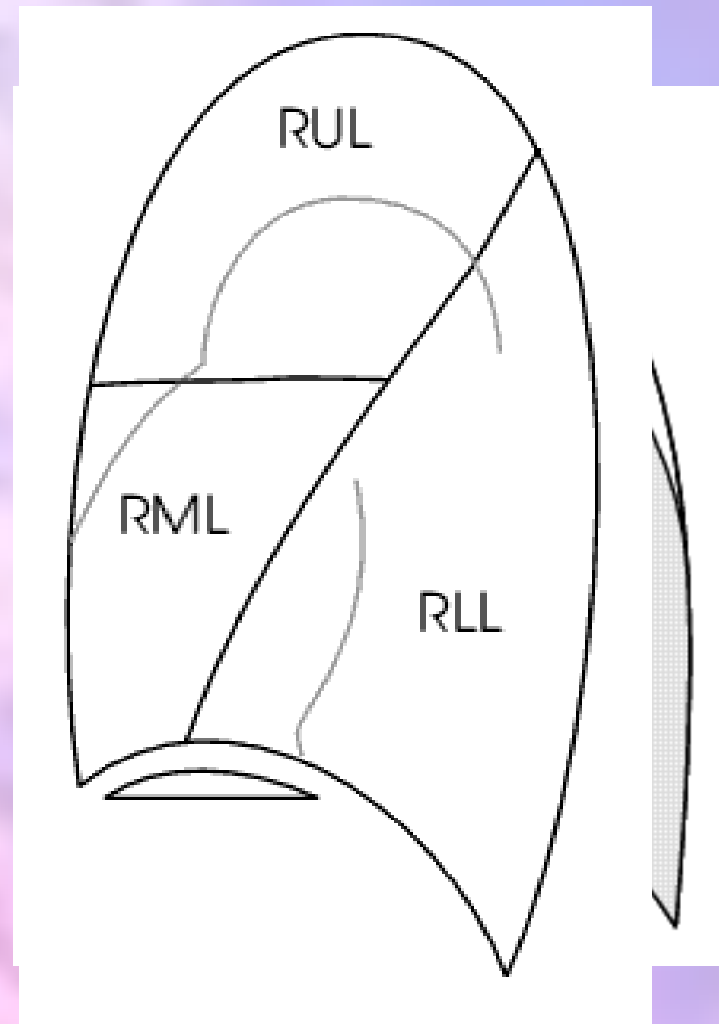
Lung Anatomy

- Right Lung
 - Superior lobe
 - Middle lobe
 - Inferior lobe
- Left Lung
 - Superior lobe
 - Inferior lobe



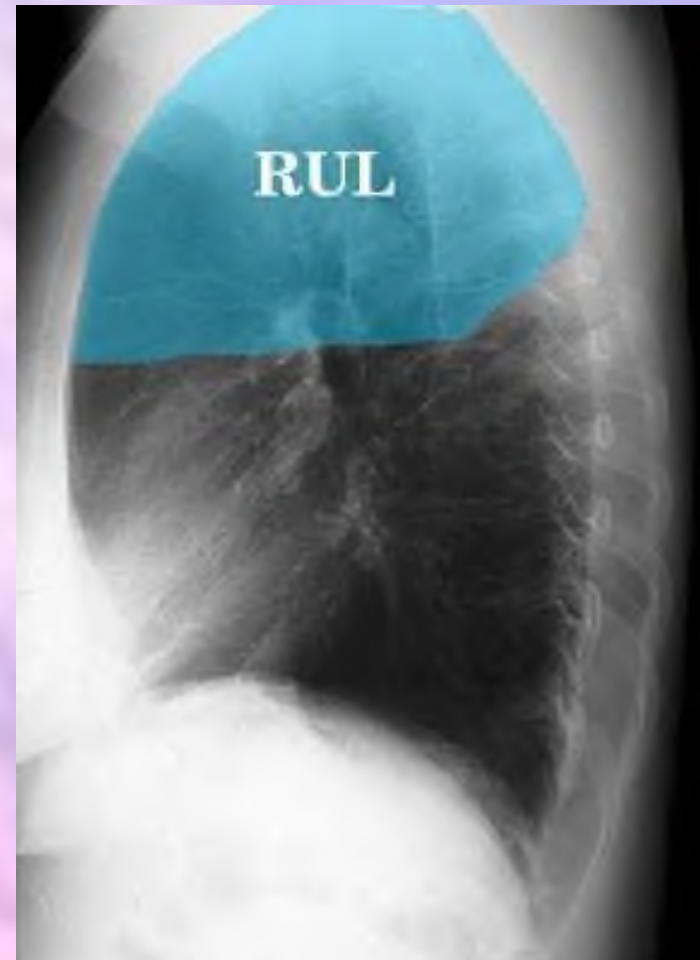Lung Anatomy on Chest X-ray

- PA View:
 - Extensive overlap
 - Lower lobes extend high
- Lateral View:
 - Extent of lower lobes



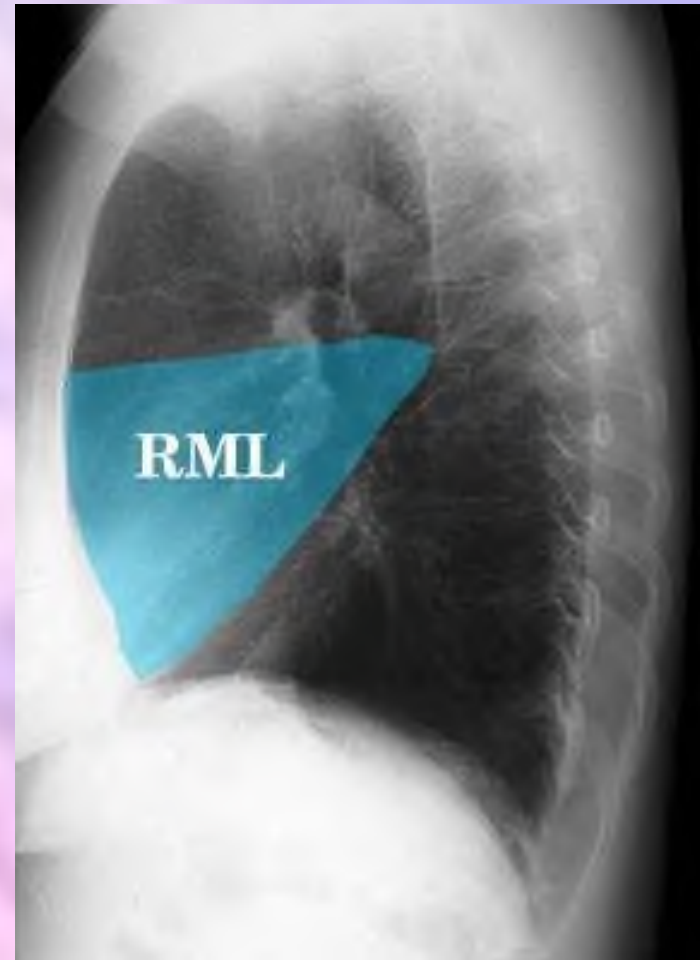
Lung Anatomy on Chest X-ray

- The right upper lobe (RUL) occupies the upper 1/3 of the right lung.
- Posteriorly, the RUL is adjacent to the first three to five ribs.
- Anteriorly, the RUL extends inferiorly as far as the 4th right anterior rib



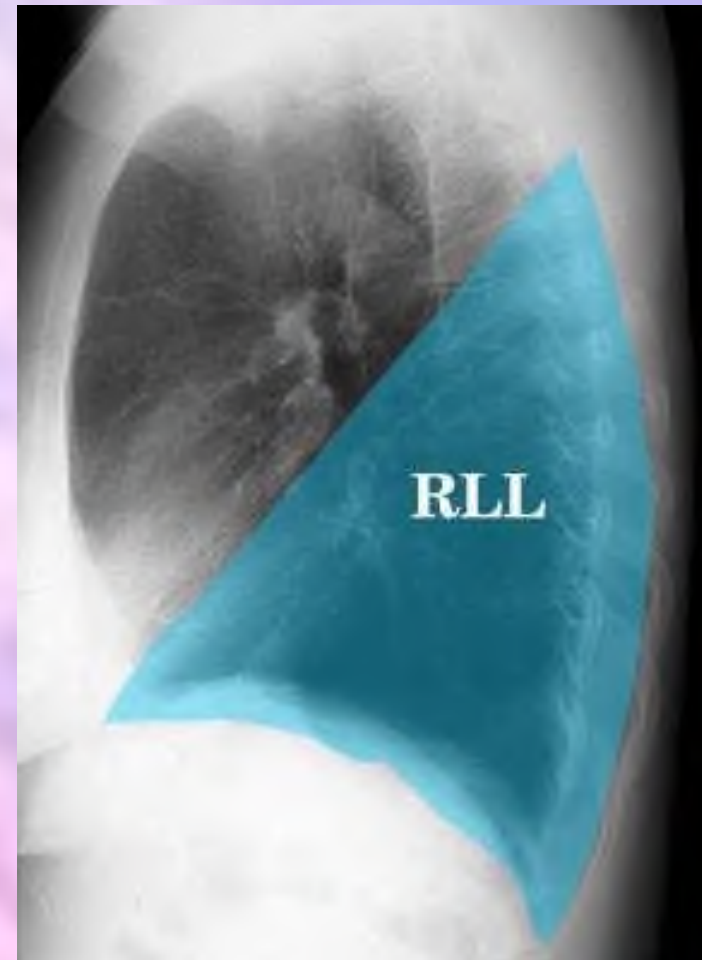Lung Anatomy on Chest X-ray

- The right middle lobe is typically the smallest of the three, and appears triangular in shape, being narrowest near the hilum



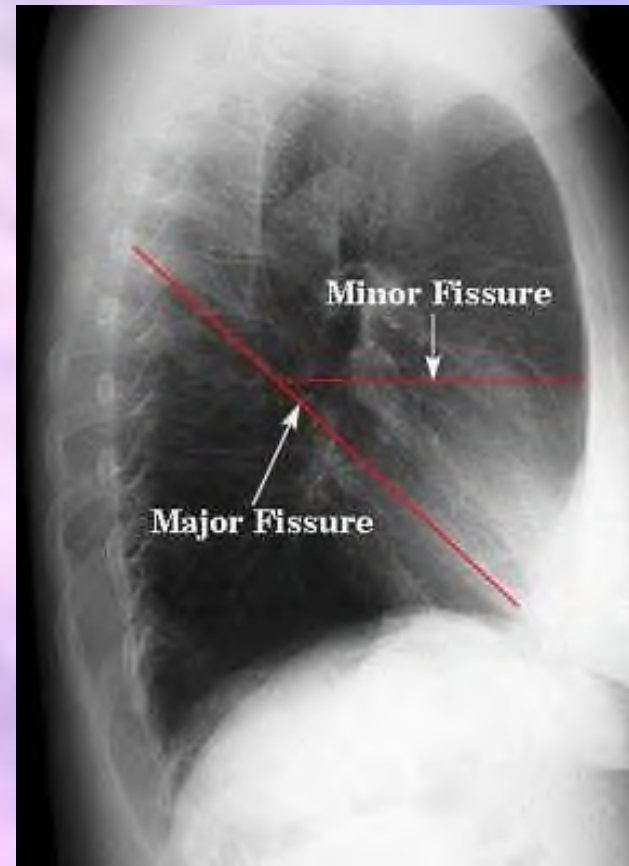
Lung Anatomy on Chest X-ray

- The right lower lobe is the largest of all three lobes, separated from the others by the major fissure.
- Posteriorly, the RLL extend as far superiorly as the 6th thoracic vertebral body, and extends inferiorly to the diaphragm.
- Review of the lateral plain film surprisingly shows the superior extent of the RLL.



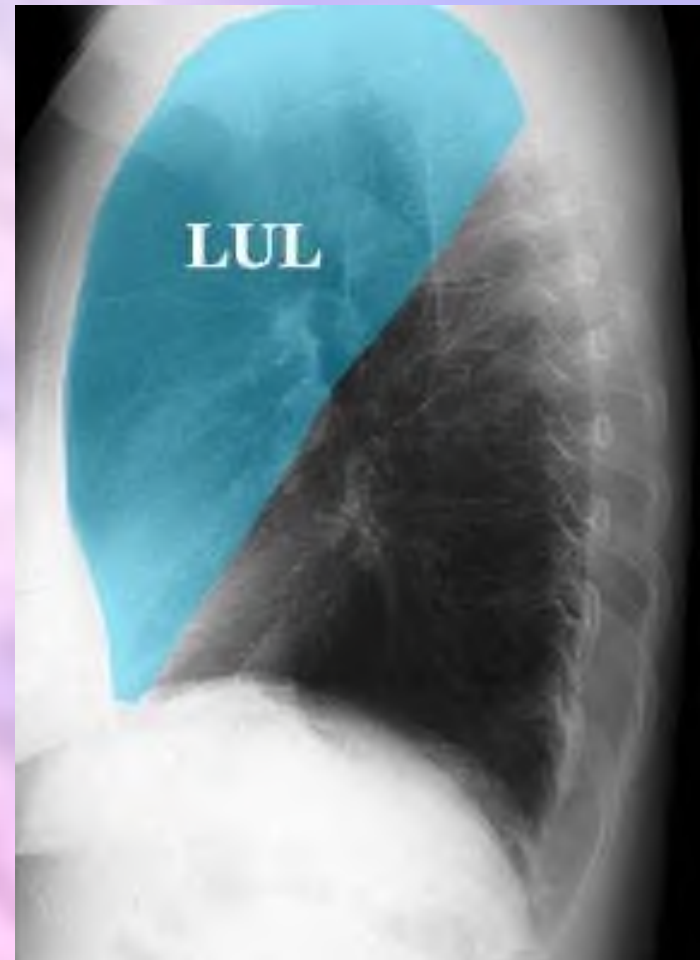Lung Anatomy on Chest X-ray

- These lobes can be separated from one another by two fissures.
- The minor fissure separates the RUL from the RML, and thus represents the visceral pleural surfaces of both of these lobes.
- Oriented obliquely, the major fissure extends posteriorly and superiorly approximately to the level of the fourth vertebral body.



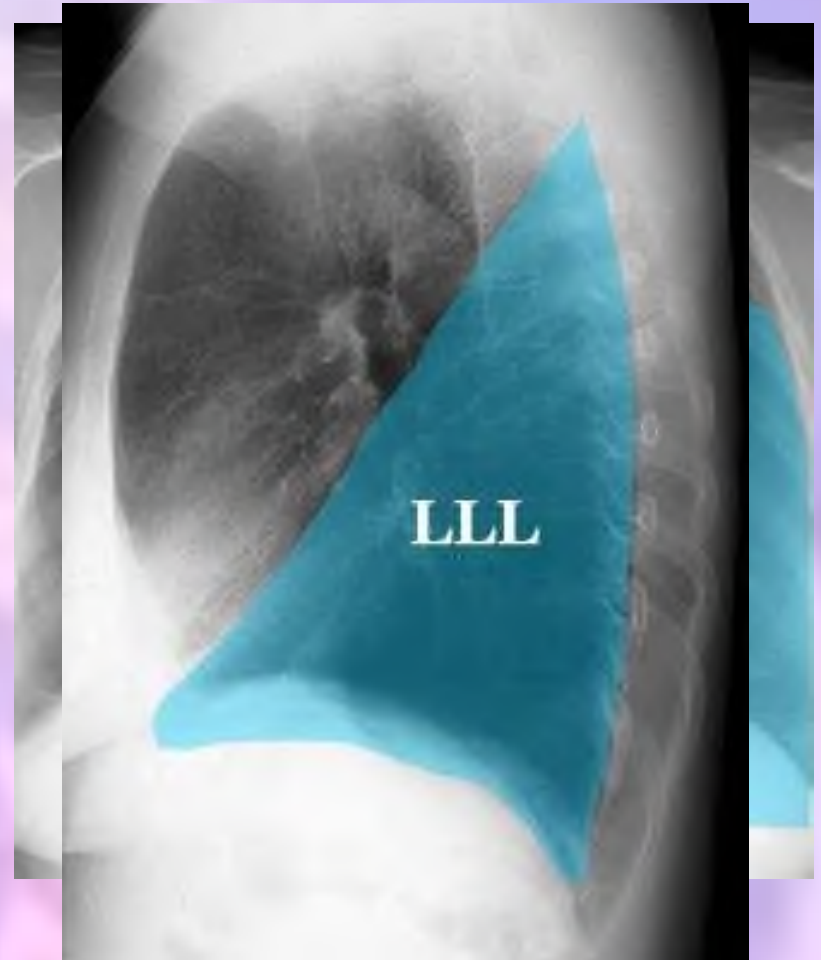Lung Anatomy on Chest X-ray

- The lobar architecture of the left lung is slightly different than the right.
- Because there is no defined left minor fissure, there are only two lobes on the left; the left upper



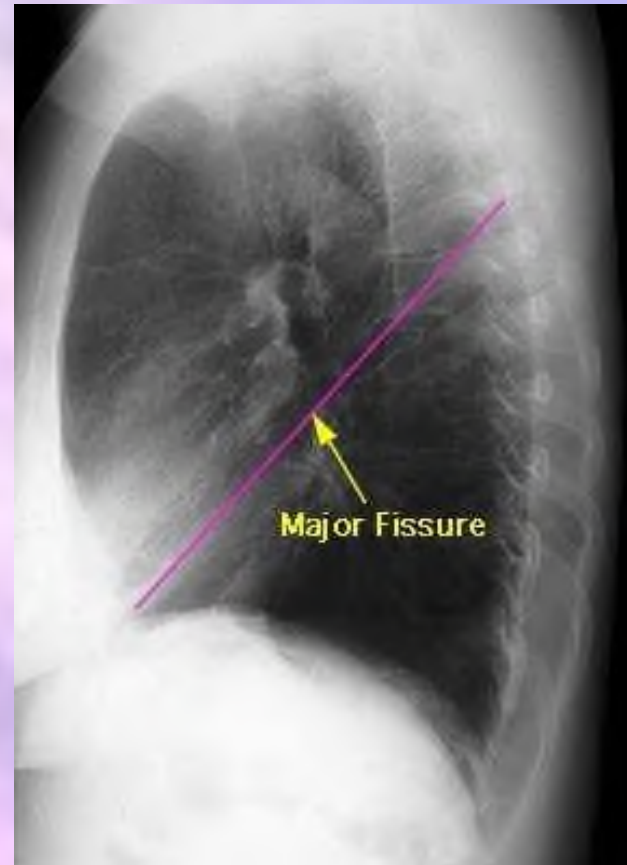
Lung Anatomy on Chest X-ray

- Left lower lobes



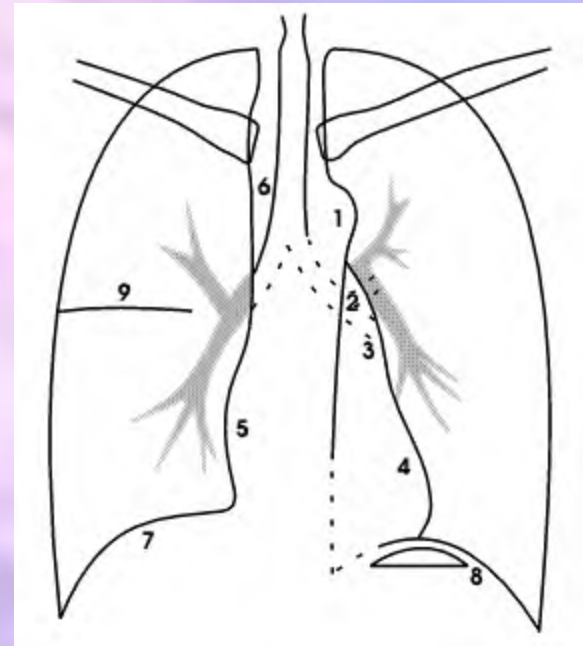
Lung Anatomy on Chest X-ray

- These two lobes are separated by a major fissure, identical to that seen on the right side, although often slightly more inferior in location.
- The portion of the left lung that corresponds anatomically to the right middle lobe is incorporated into the left upper lobe.



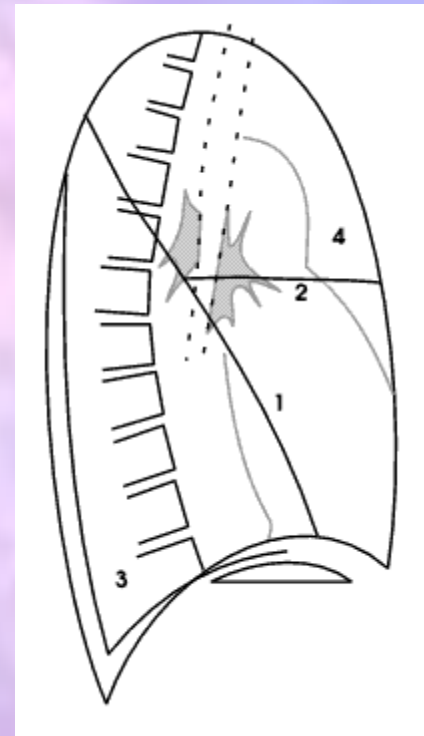
The Normal Chest X-ray

- PA View:
 1. Aortic arch
 2. Pulmonary trunk
 3. Left atrial appendage
 4. Left ventricle
 5. Right ventricle
 6. Superior vena cava
 7. Right hemidiaphragm
 8. Left hemidiaphragm
 9. Horizontal fissure



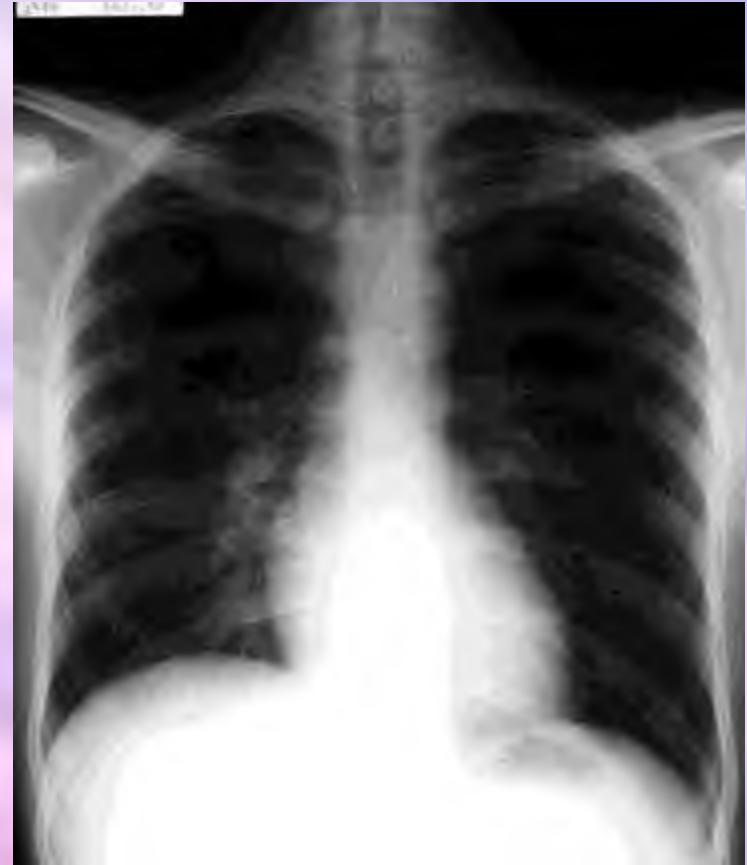The Normal Chest X-ray

- Lateral View:
 1. Oblique fissure
 2. Horizontal fissure
 3. Thoracic spine and retrocardiac space
 4. Retrosternal space

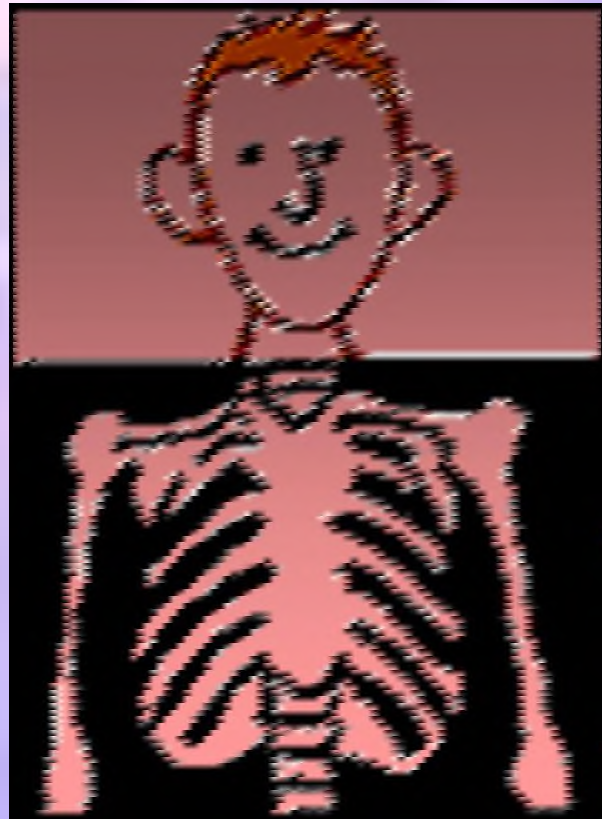

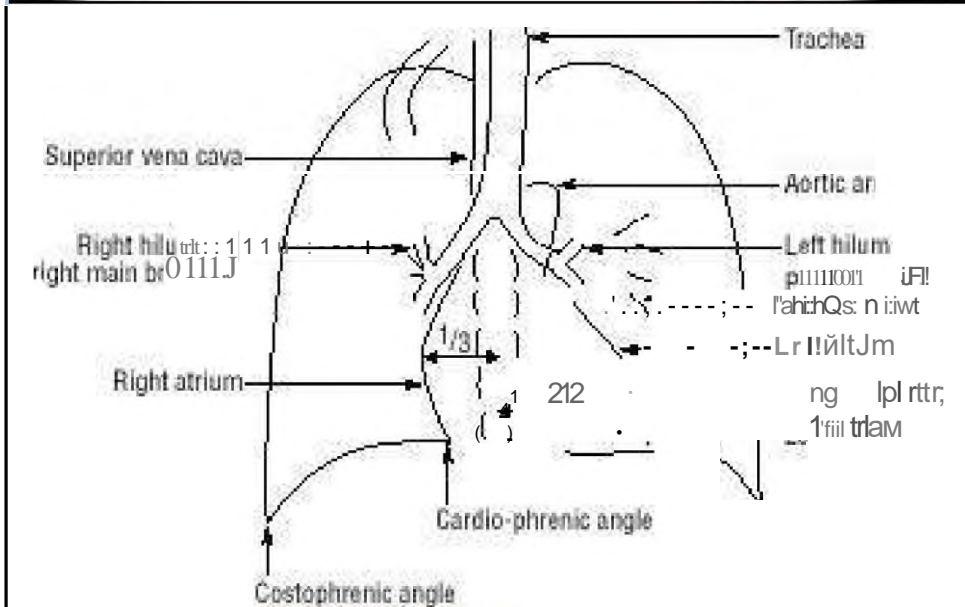
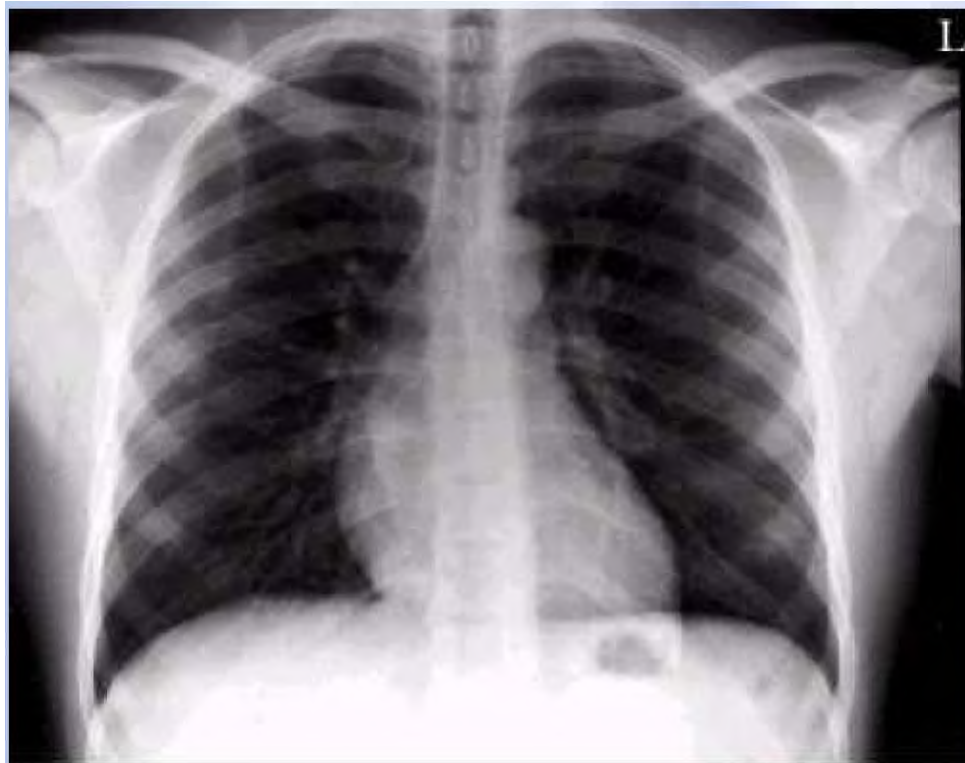
The Silhouette Sign

- An intra-thoracic radio-opacity, if in anatomic contact with a border of heart or aorta, will obscure that border. An intra-thoracic lesion not anatomically contiguous with a border or a normal structure will not obliterate that border.



Putting It All Together





Understanding Pathological Changes

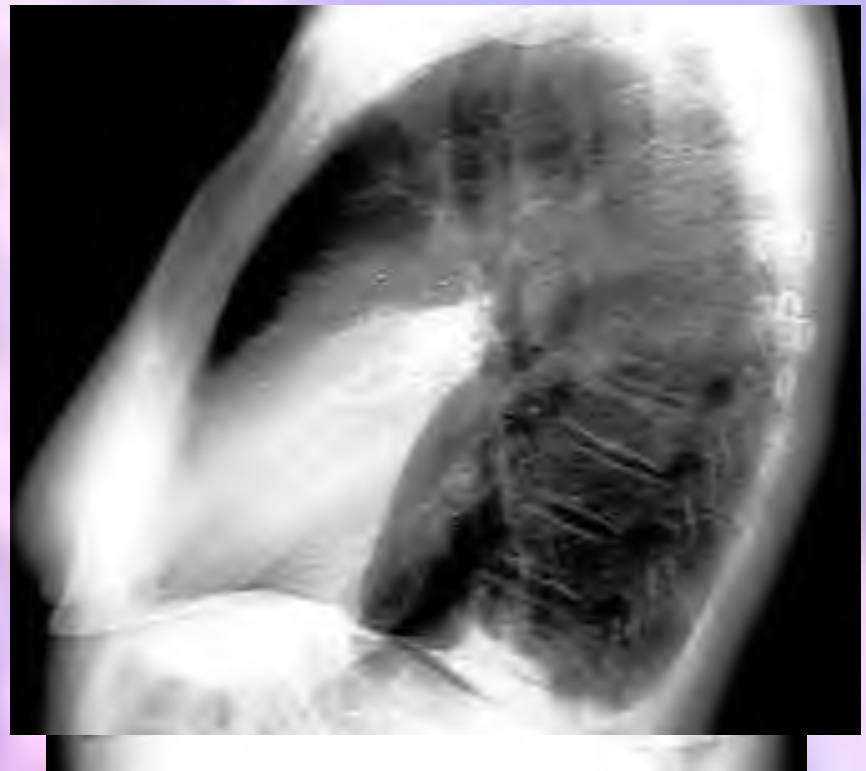
- Most disease states replace air with a pathological process
- Each tissue reacts to injury in a predictable fashion
- Lung injury or pathological states can be either a generalized or localized process

Liquid Density

Liquid density		Increased air density
Generalized	Localized	
Diffuse alveolar Diffuse interstitial Mixed Vascular	Infiltrate Consolidation Cavitation Mass Congestion Atelectasis	Localized airway obstruction Diffuse airway obstruction Emphysema Bulla

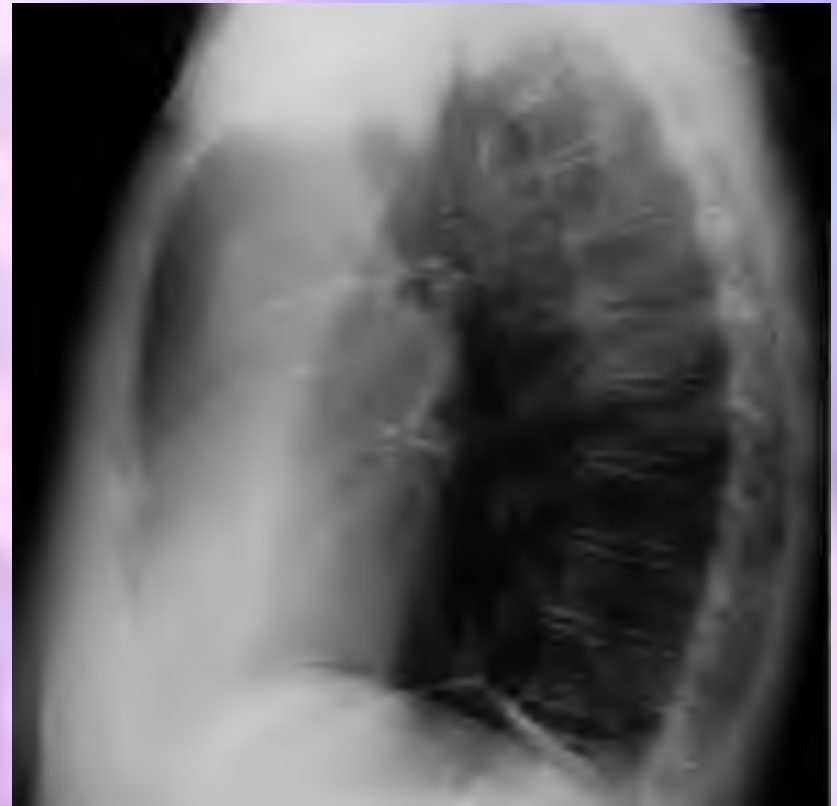
Consolidation

- Lobar consolidation:
 - Alveolar space filled with inflammatory exudate
 - Interstitium and architecture remain intact
 - The airway is patent
 - Radiologically:
 - A density corresponding to a segment or lobe
 - Airbronchogram, and
 - No significant loss of lung volume



Atelectasis

- Loss of air
- Obstructive atelectasis:
 - No ventilation to the lobe beyond obstruction
 - Radiologically:
 - Density corresponding to a segment or lobe
 - Significant loss of volume
 - Compensatory hyperinflation of normal lungs

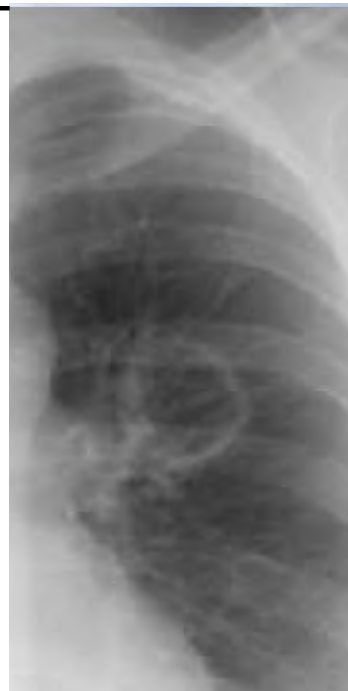
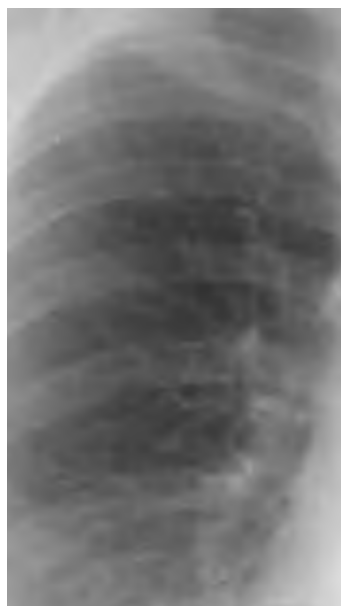
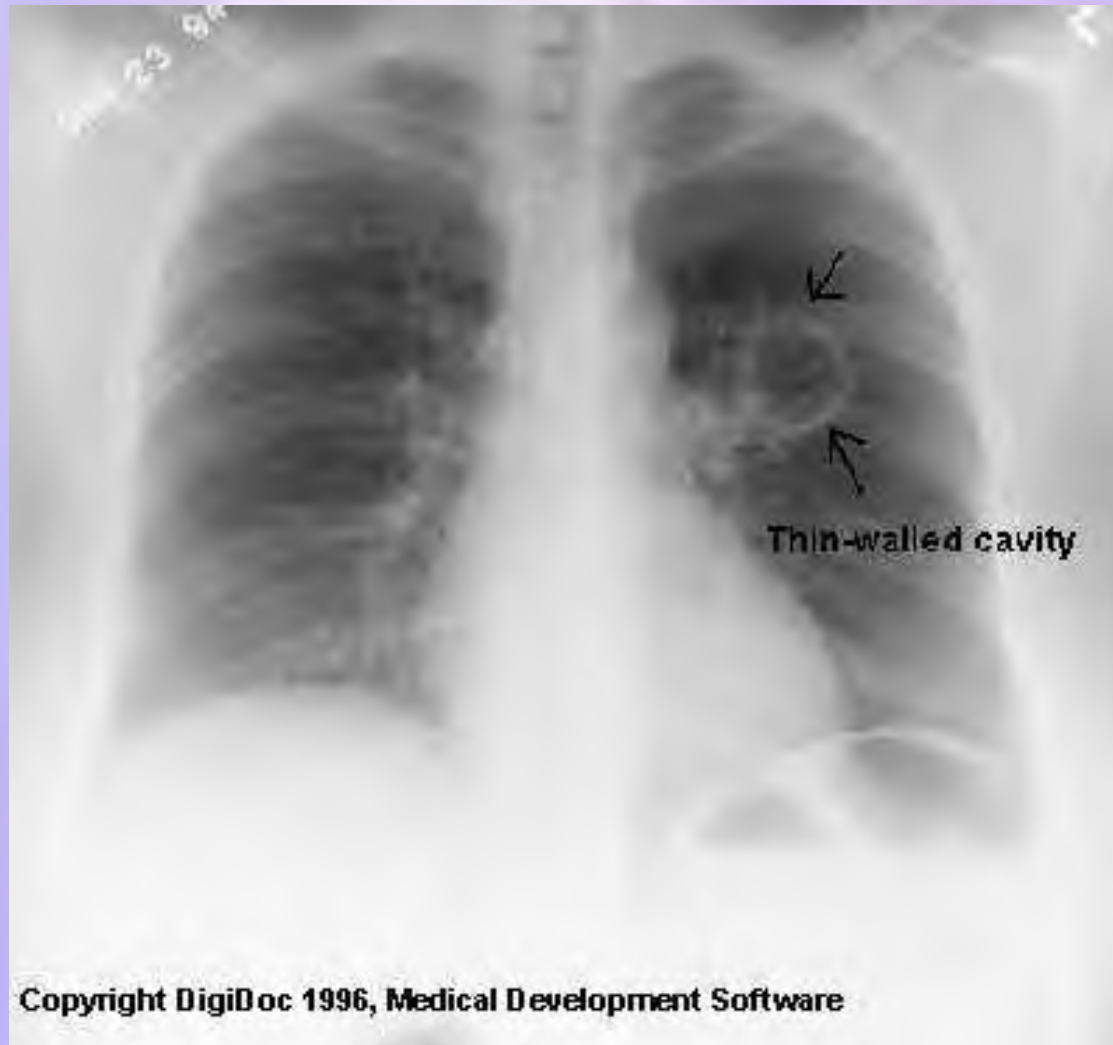
Stages of Evaluating an Abnormality

1. Identification of abnormal shadows
2. Localization of lesion
3. Identification of pathological process
4. Identification of etiology
5. Confirmation of clinical suspension
 - Complex problems
 - Introduction of contrast medium
 - CT chest
 - MRI scan



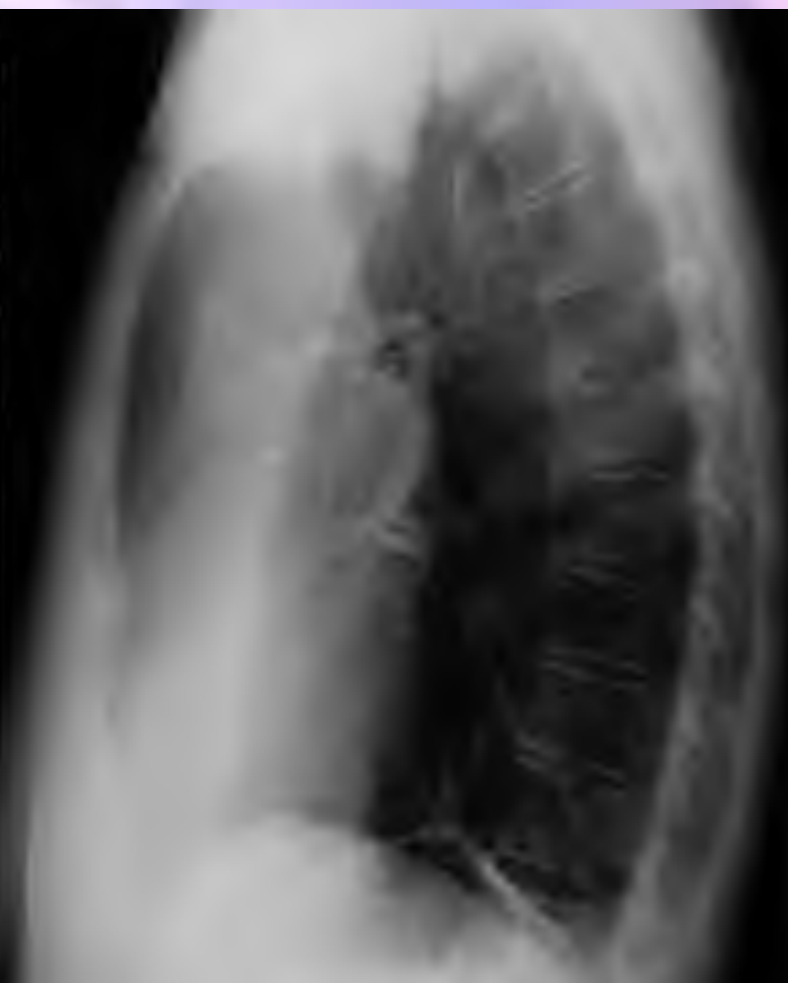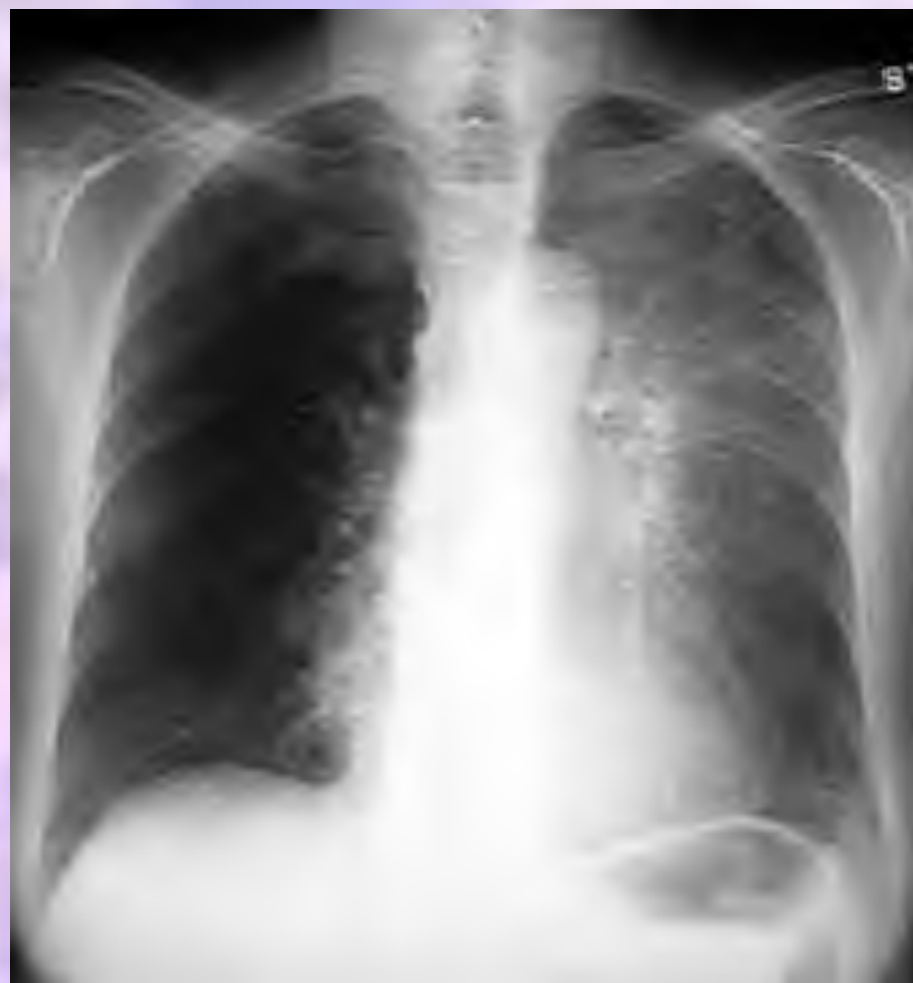Putting It Into Practice

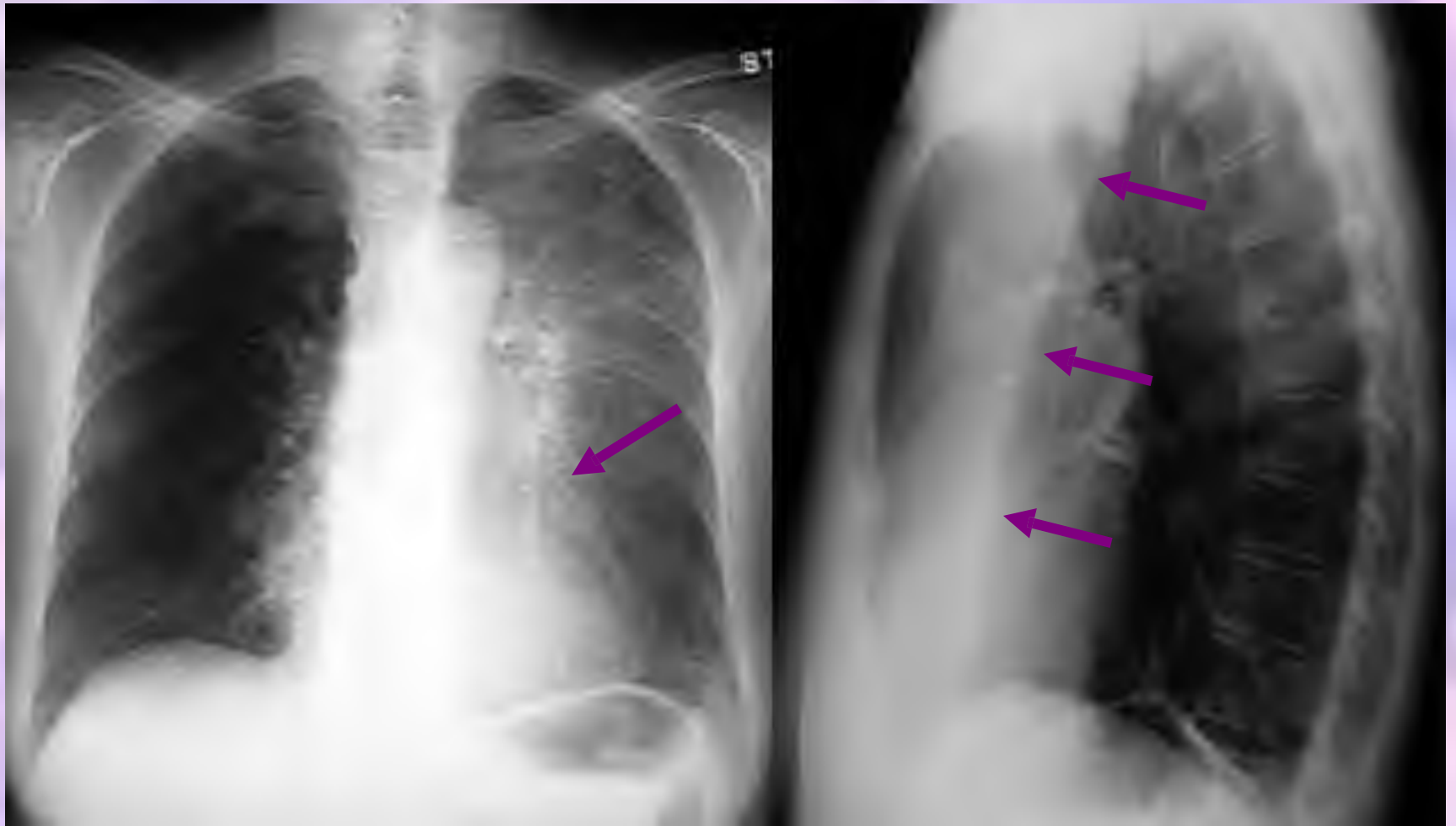




A single, 3cm relatively thin-walled cavity is noted in the left midlung. This finding is most typical of squamous cell carcinoma (SCC). One-third of SCC masses show cavitation

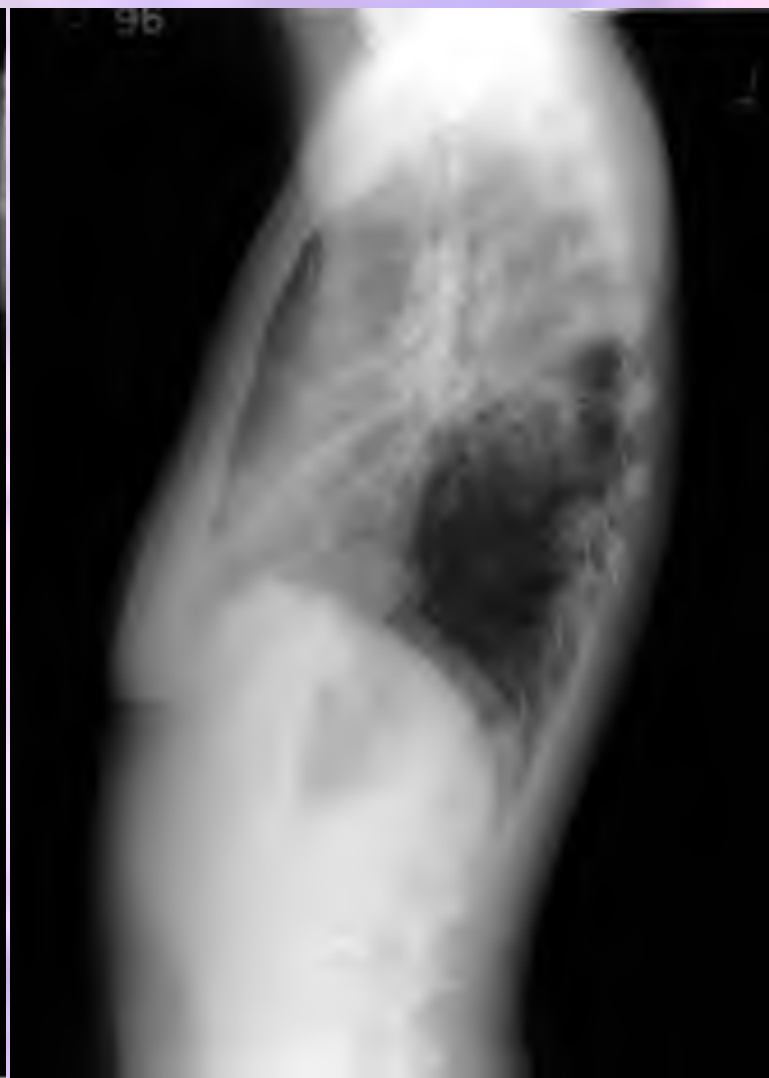
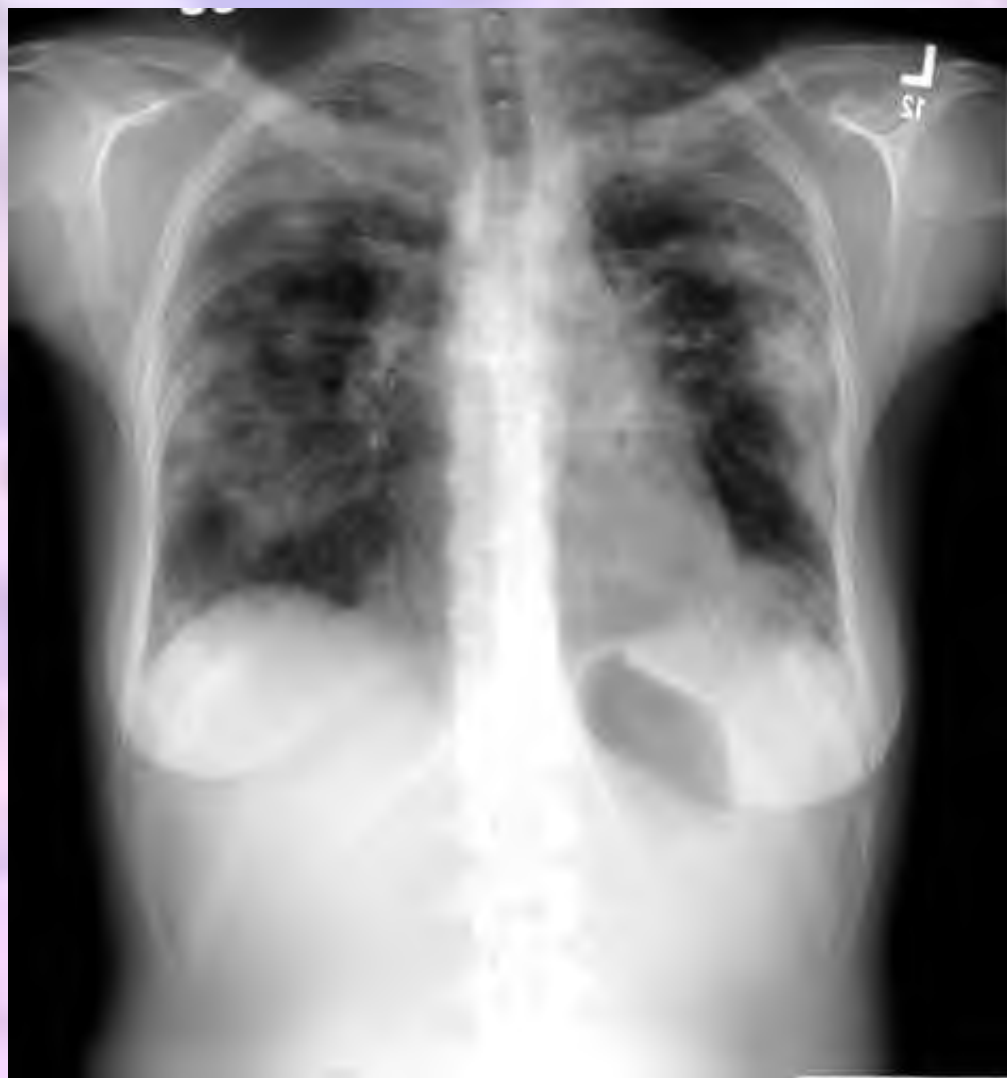Case 2

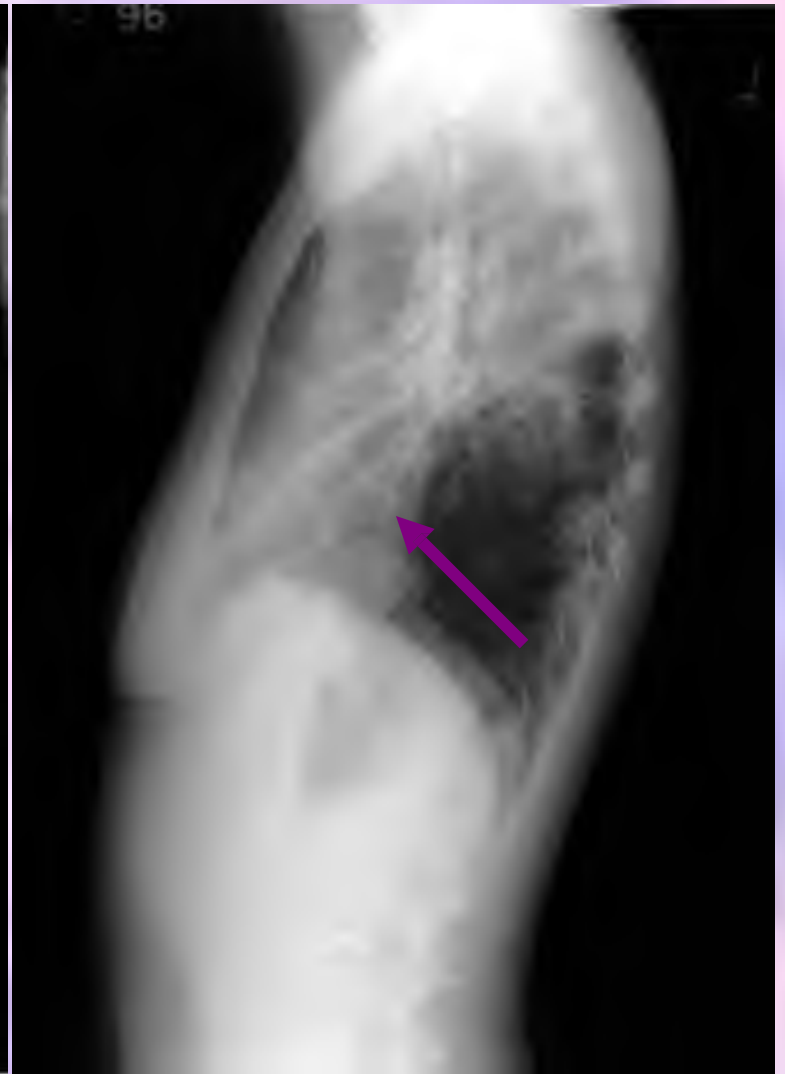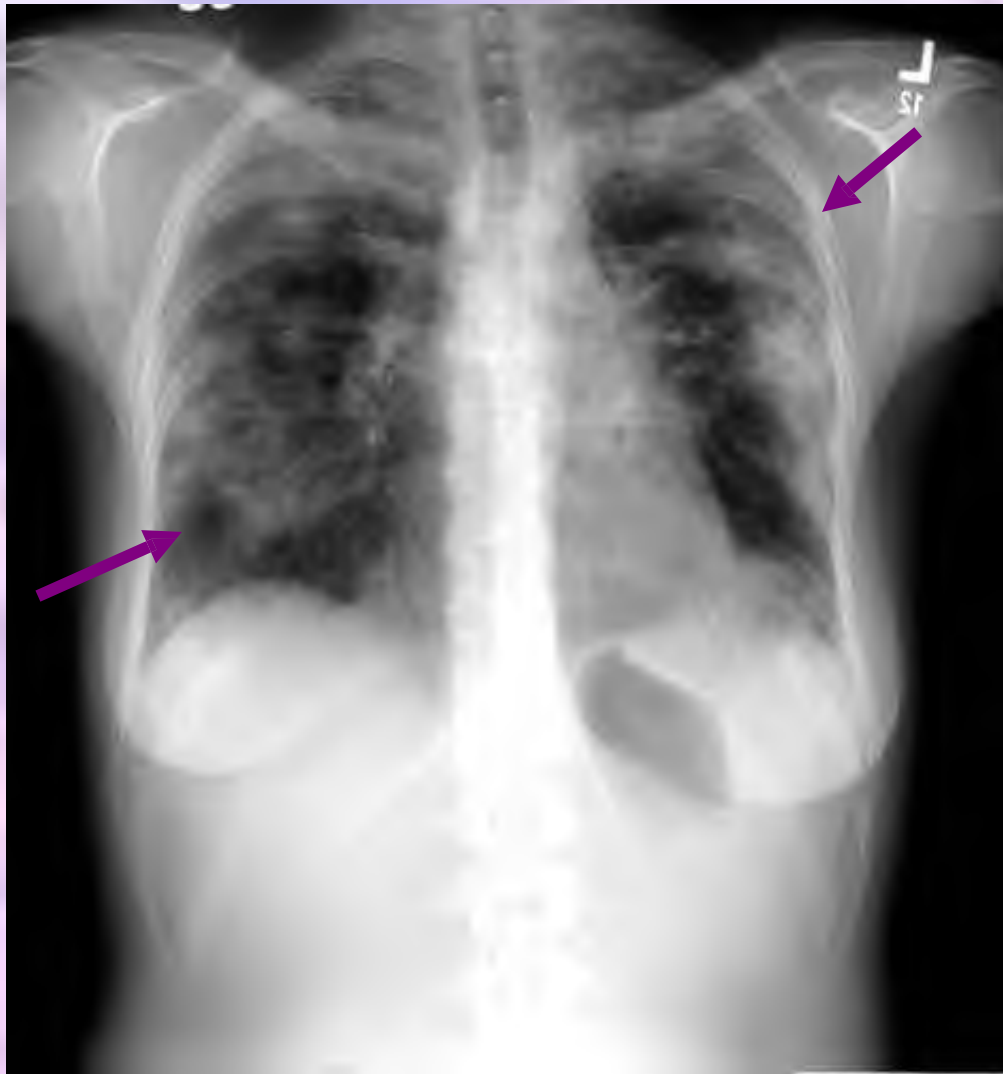




LUL Atelectasis: Loss of heart borders/silhouetting. Notice over inflation on unaffected lung

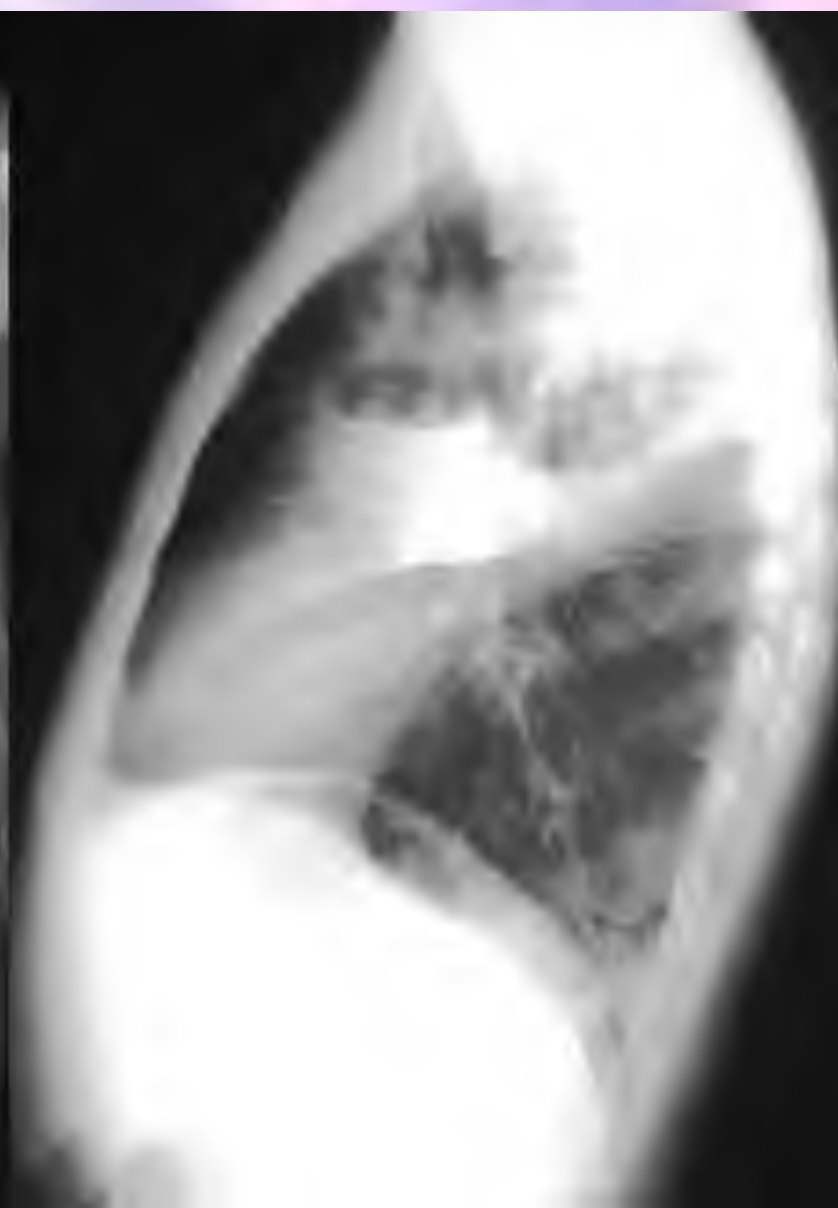
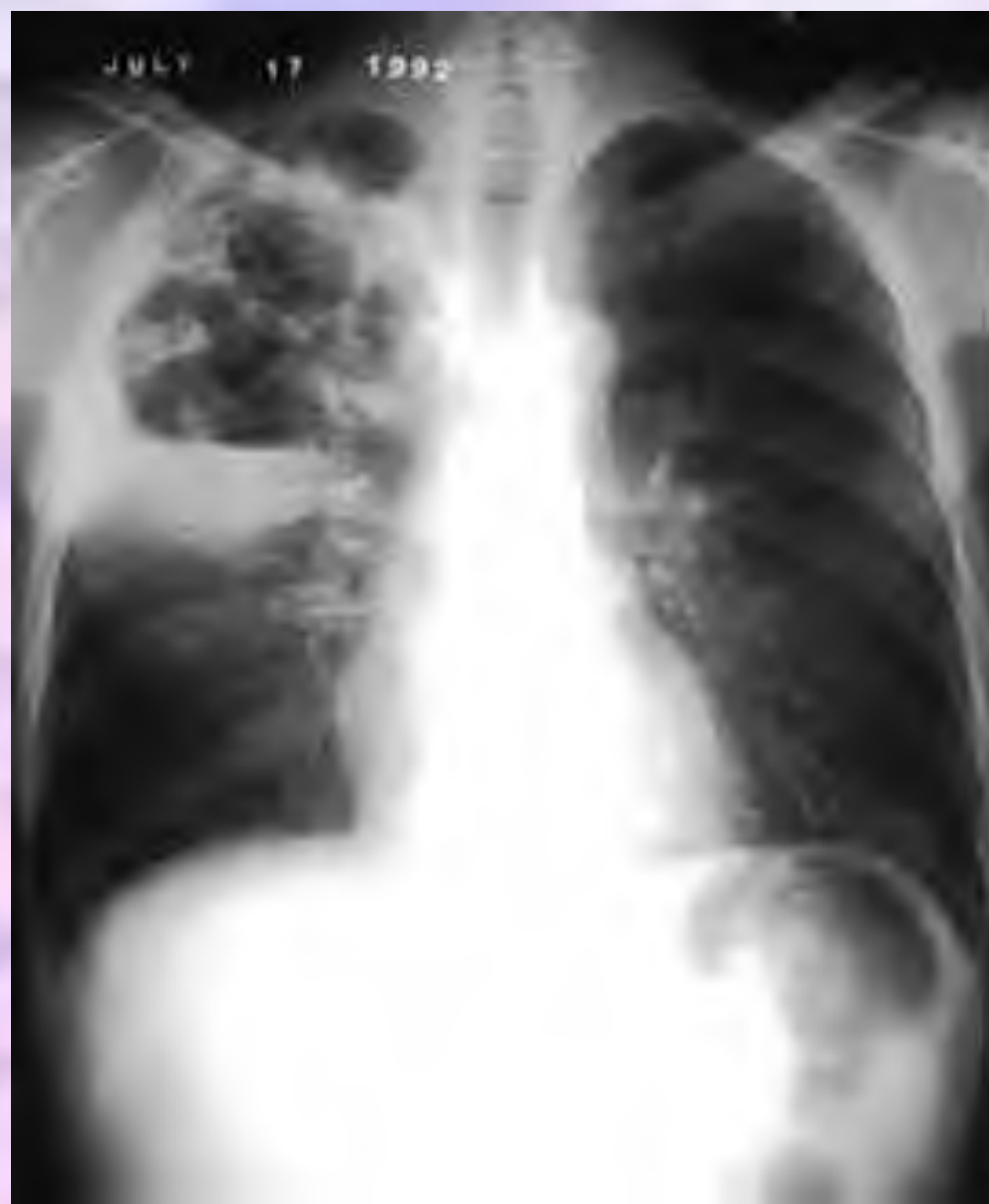Case 3

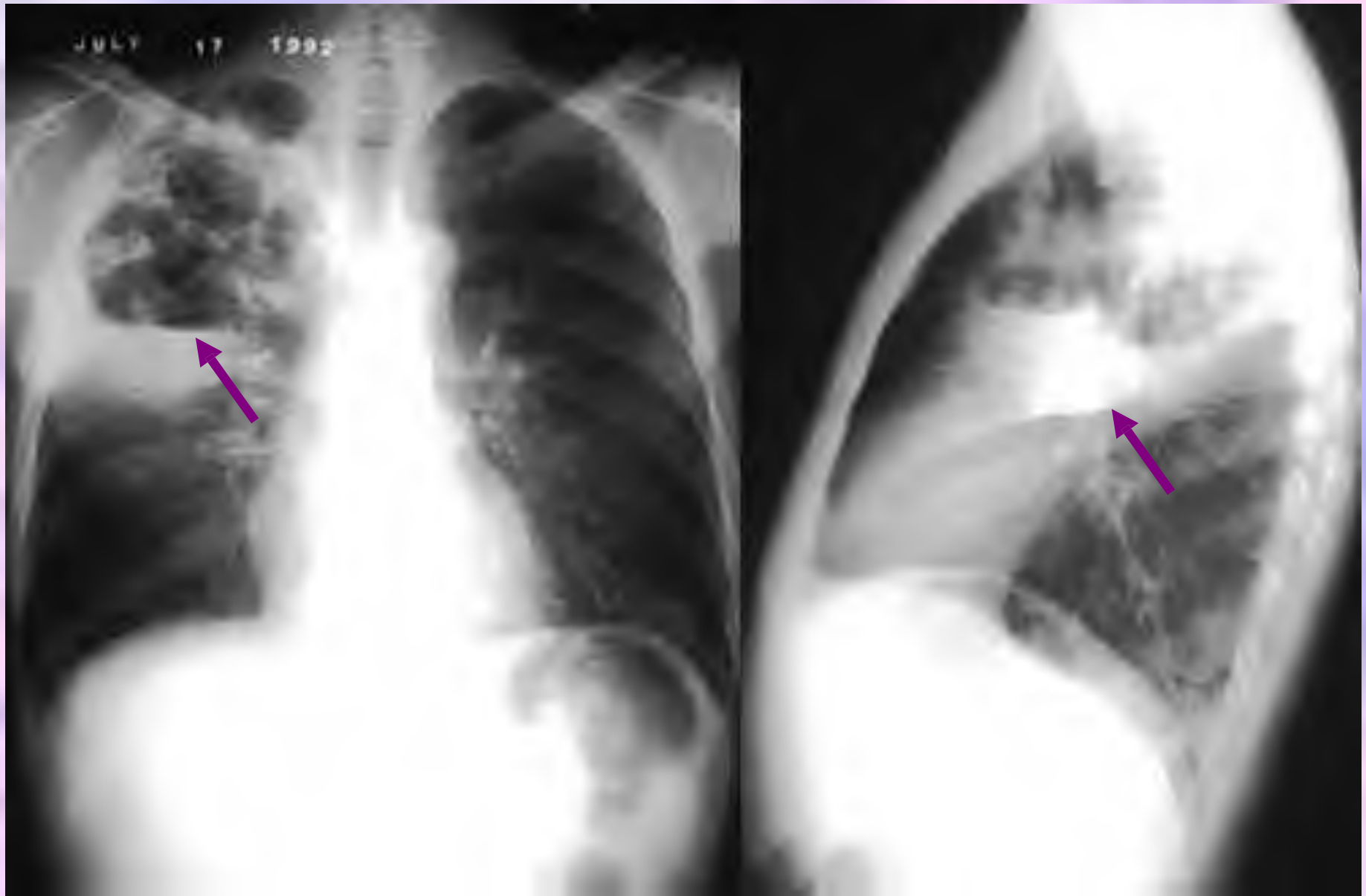



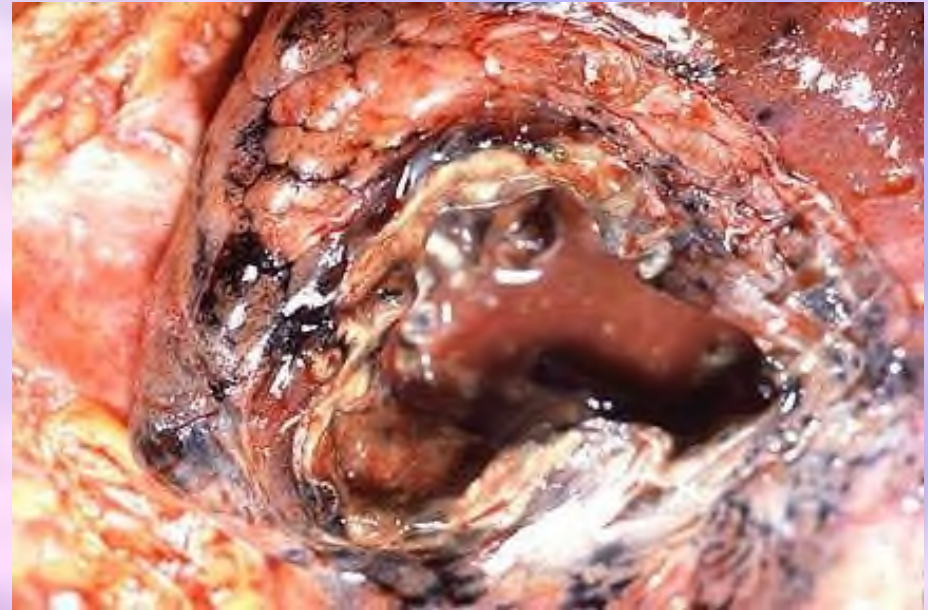
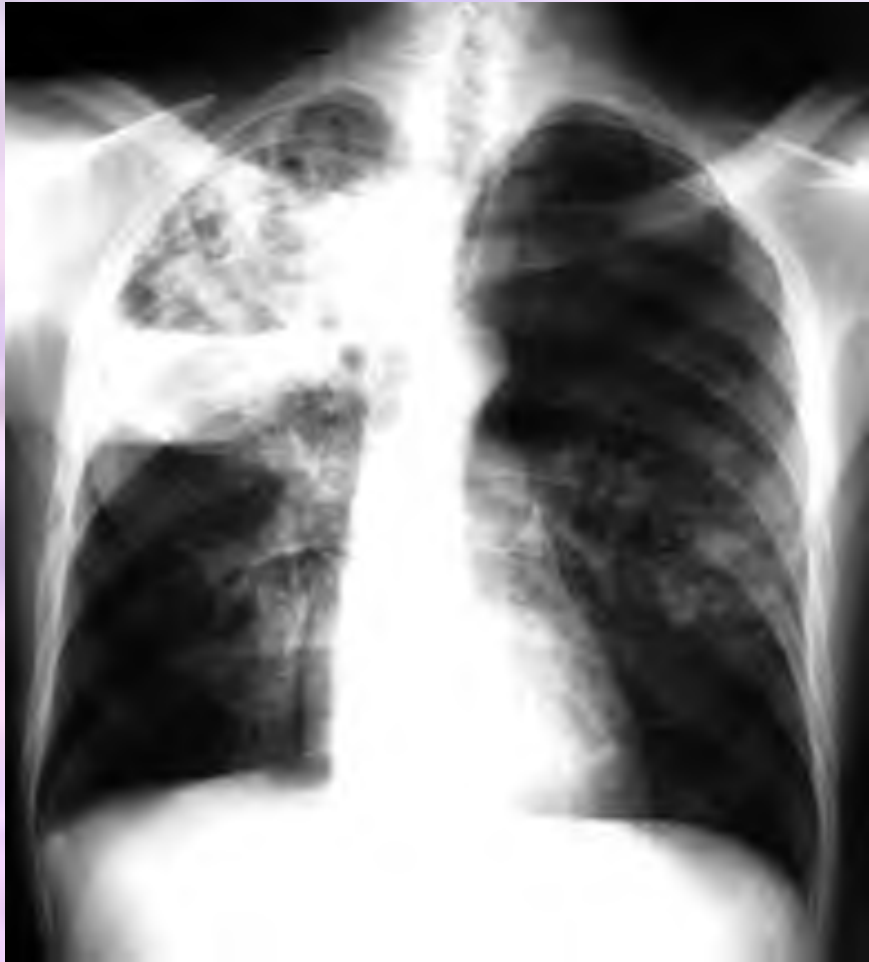Right Middle and Left Upper Lobe Pneumonia

Case 4



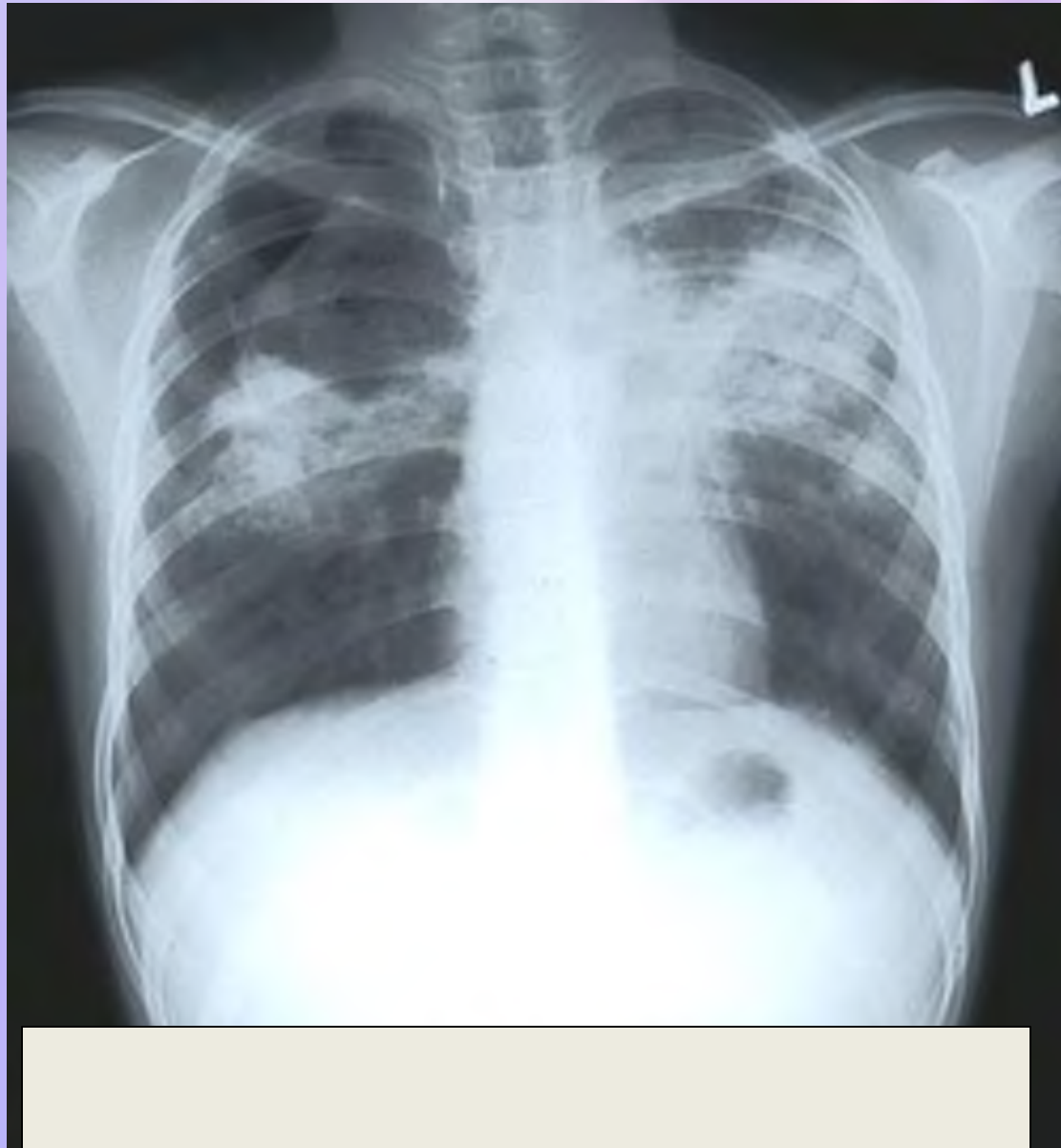

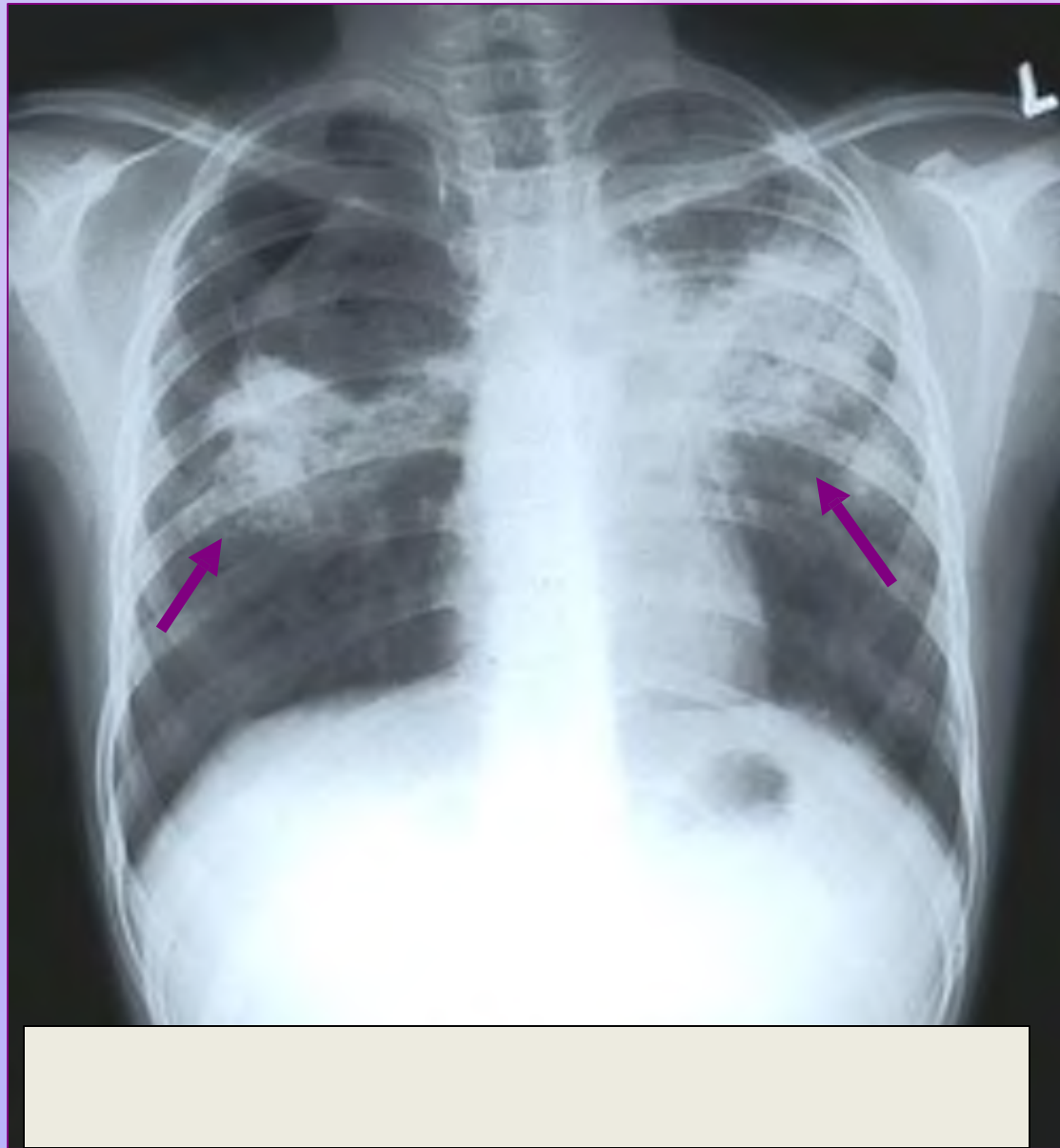
Cavitation:cystic changes in the area of consolidation due to the bacterial destruction of lung tissue. Notice air fluid level.



Cavitation

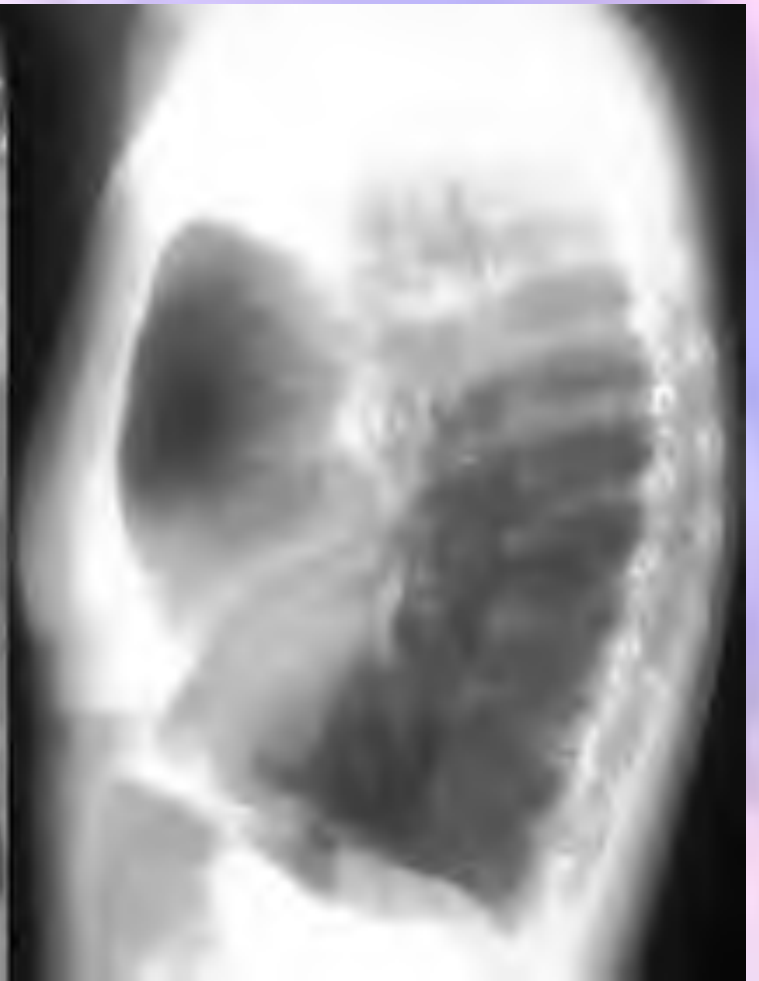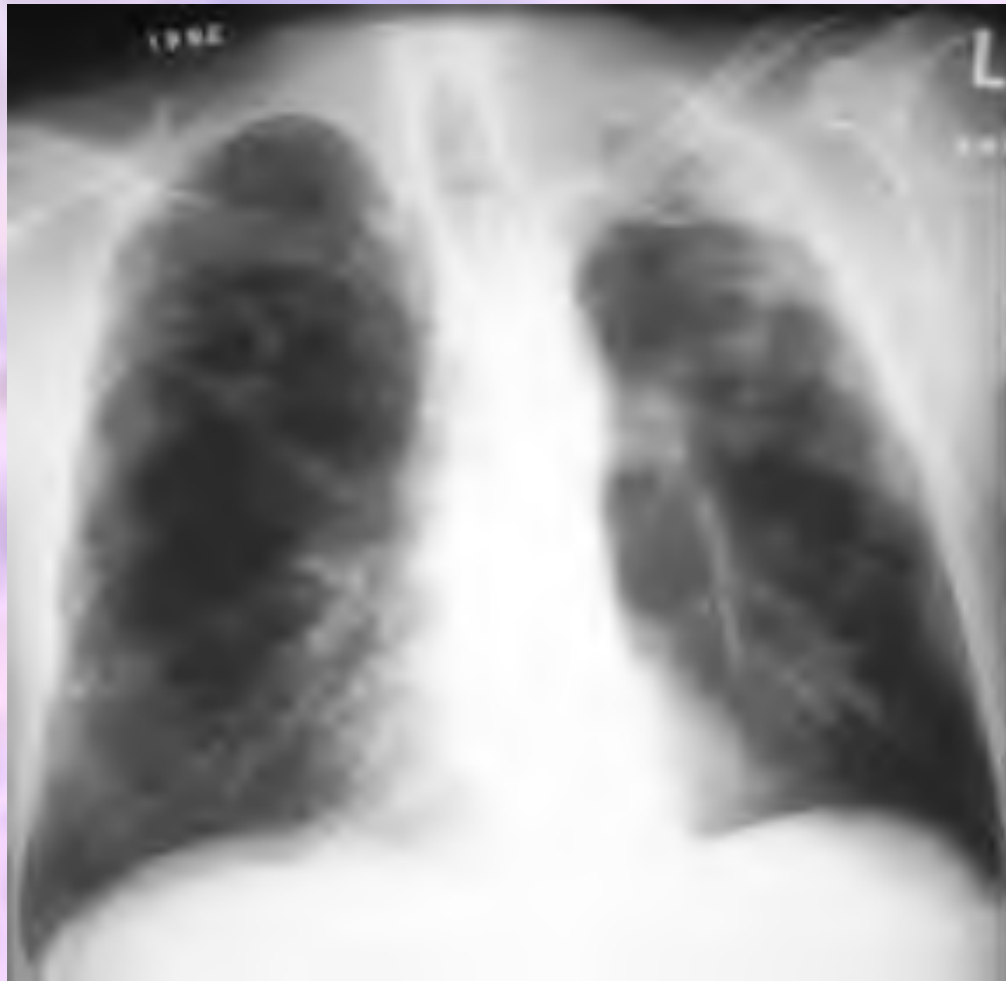Case 5

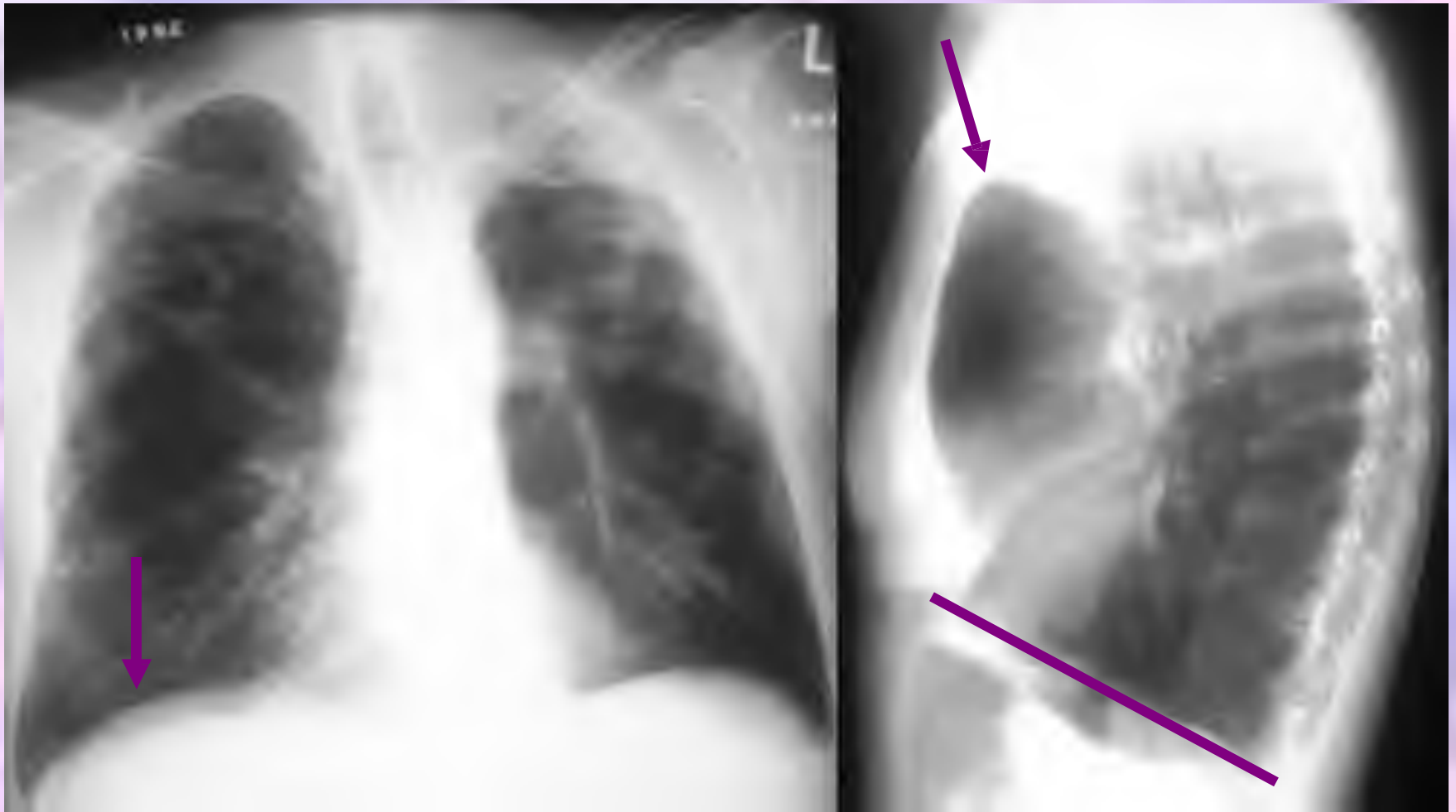




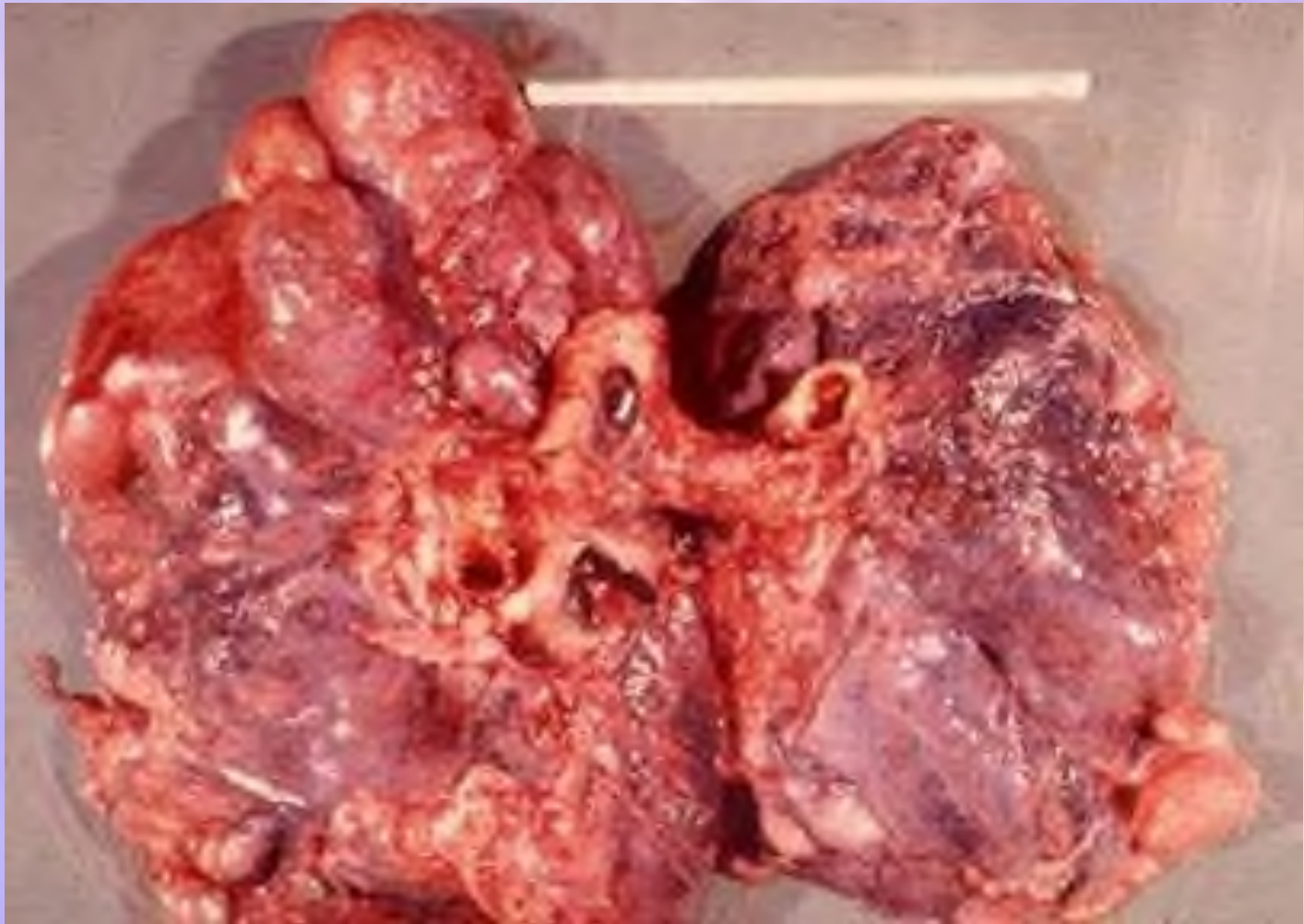Tuberculosis

Case 6



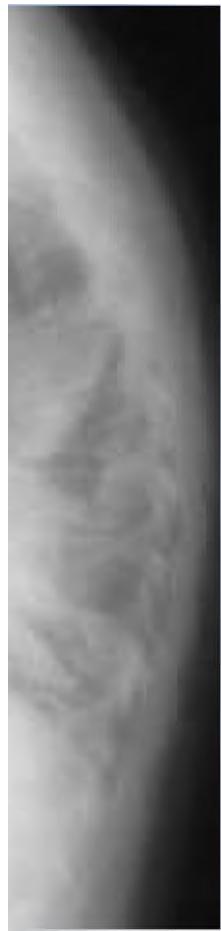
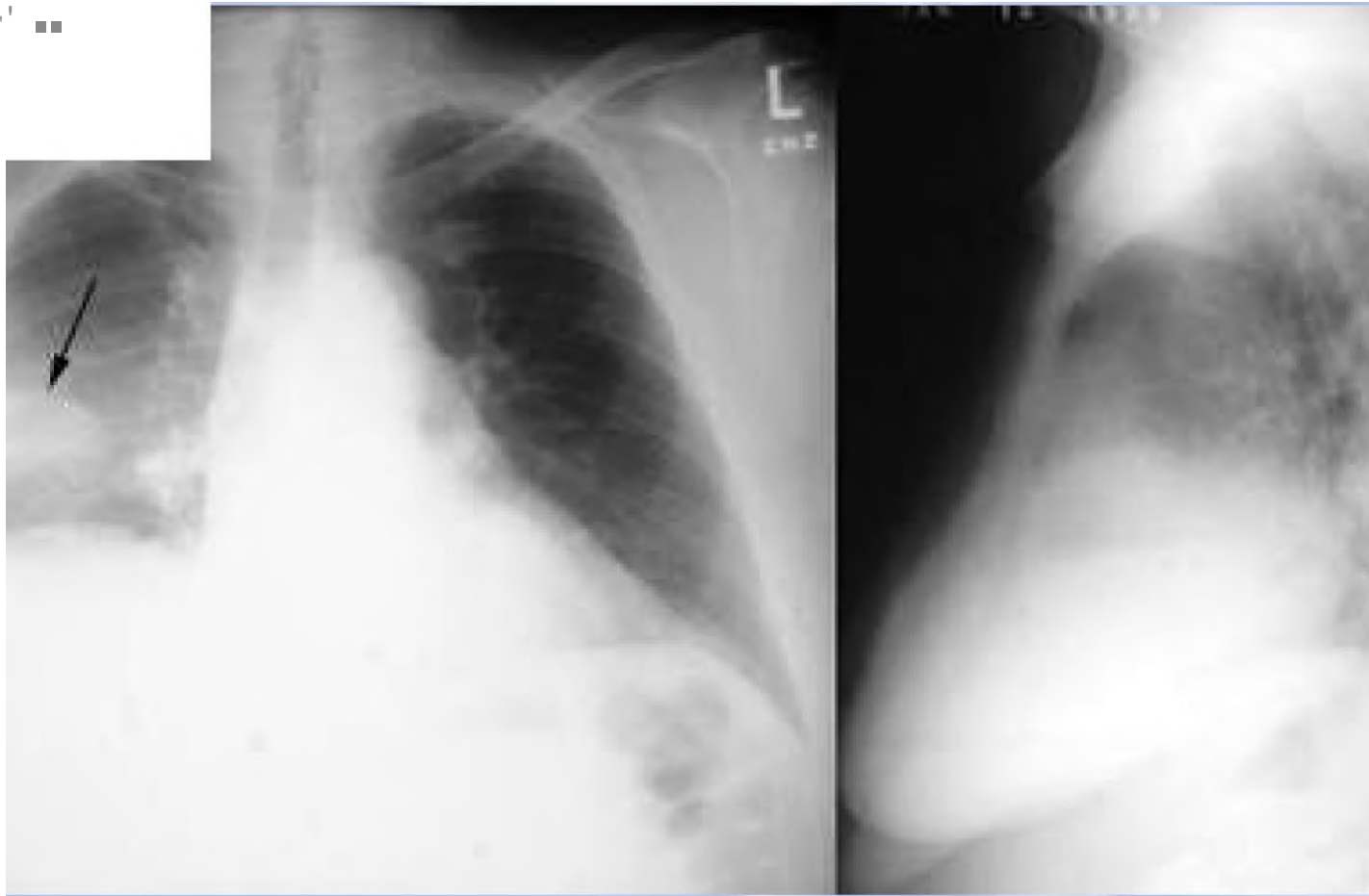
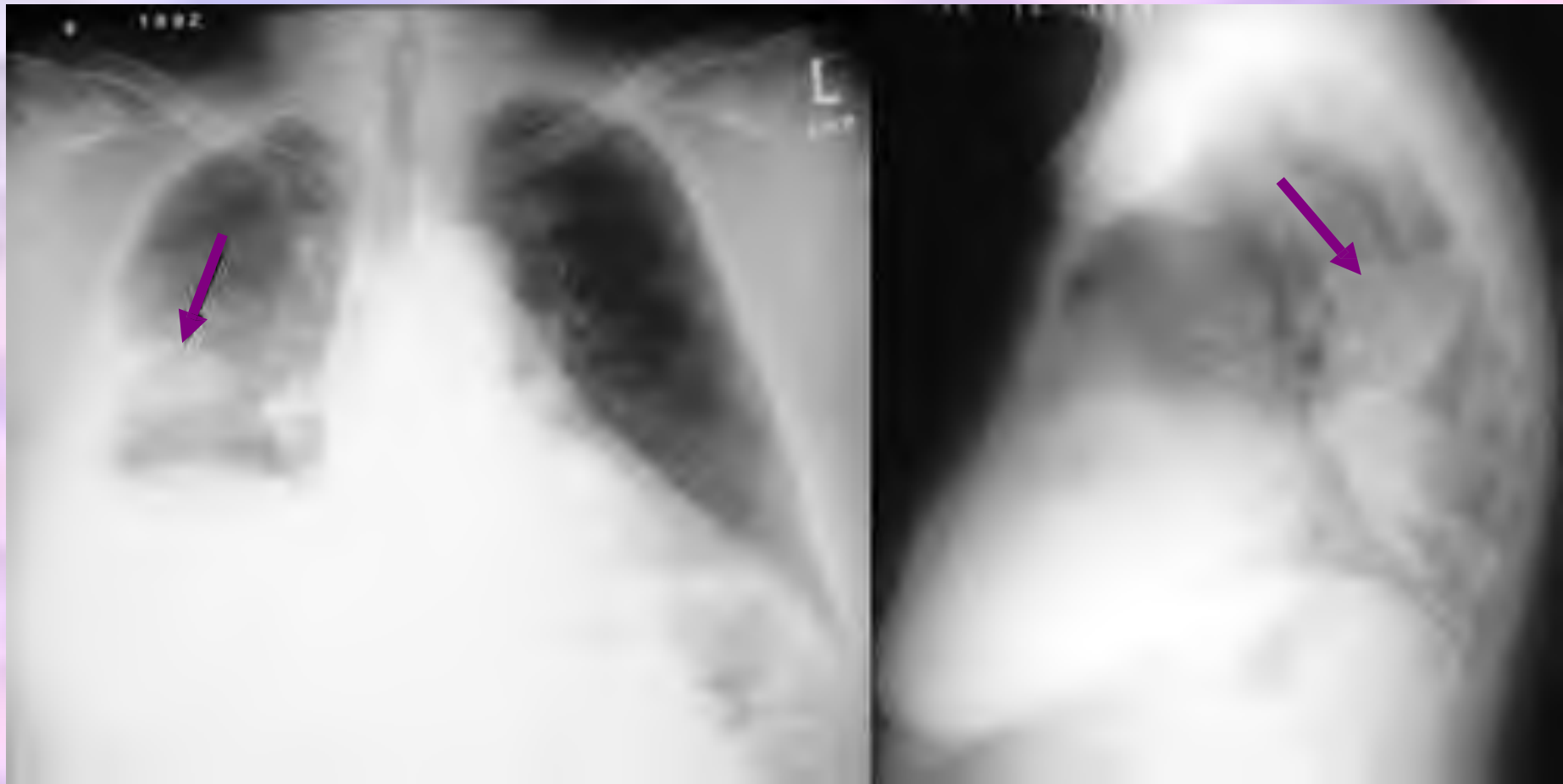COPD: increase in heart diameter, flattening of the diaphragm, and increase in the size of the retrosternal air space. In addition the upper lobes will become hyperlucent due to destruction of the lung tissue.



Chronic emphysema effect on the lungs

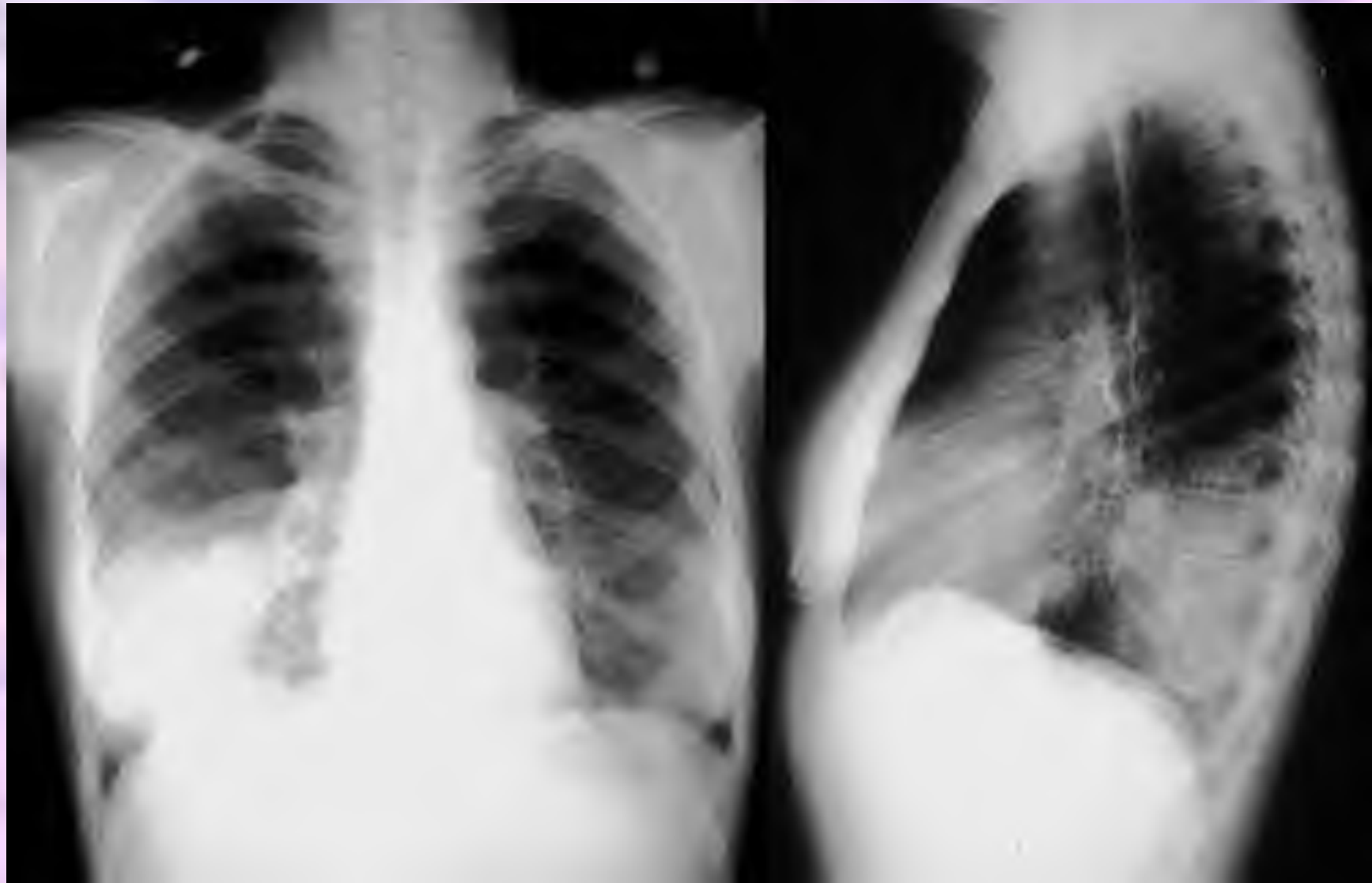
Case 7

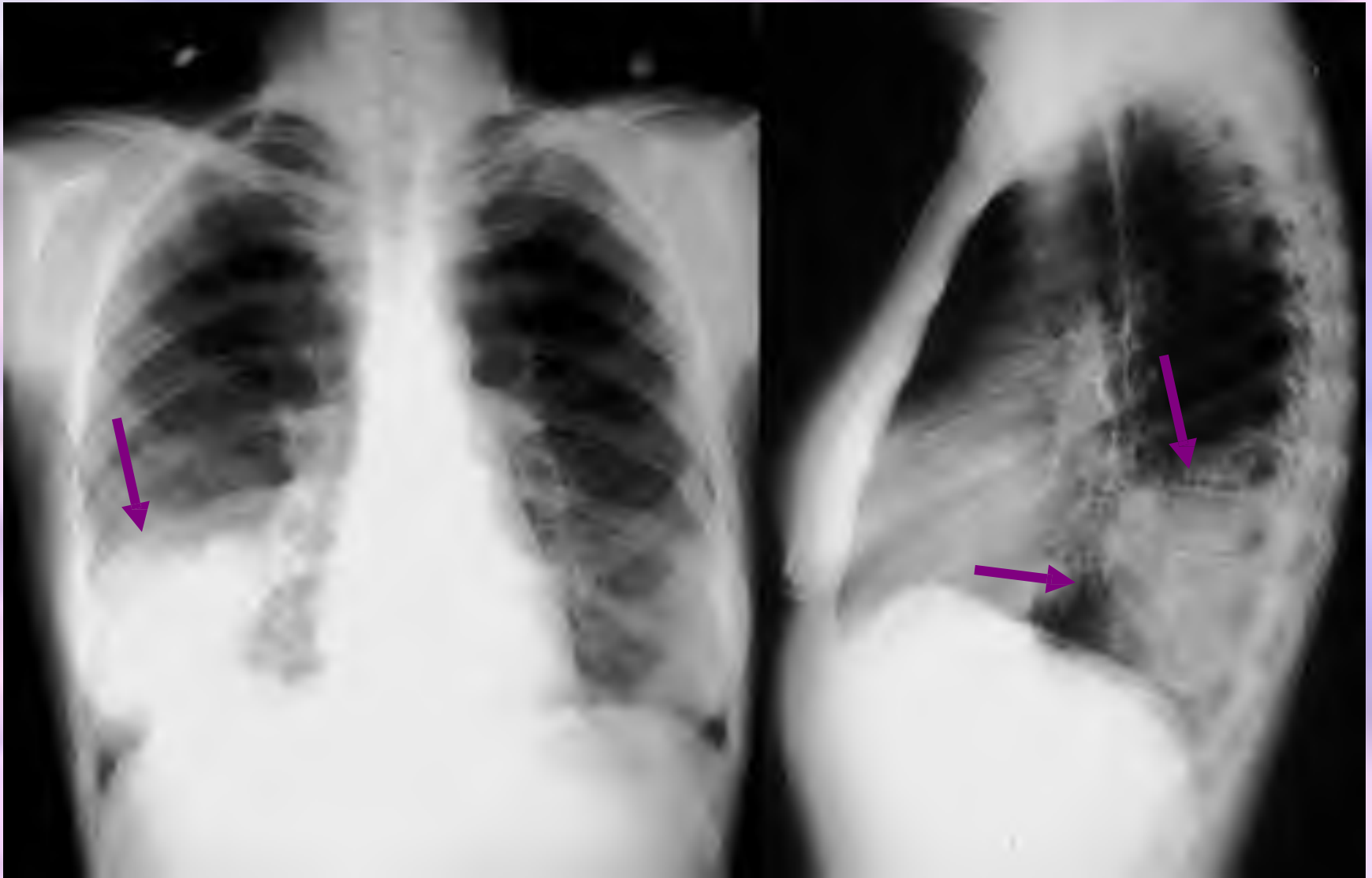




Pseudotumor: fluid has filled the minor fissure creating a density that resembles a tumor (arrow). Recall that fluid and soft tissue are indistinguishable on plain film. Further analysis, however, reveals a classic pleural effusion in the right pleura. Note the right lateral gutter is blunted and the right diaphragm is obscured.

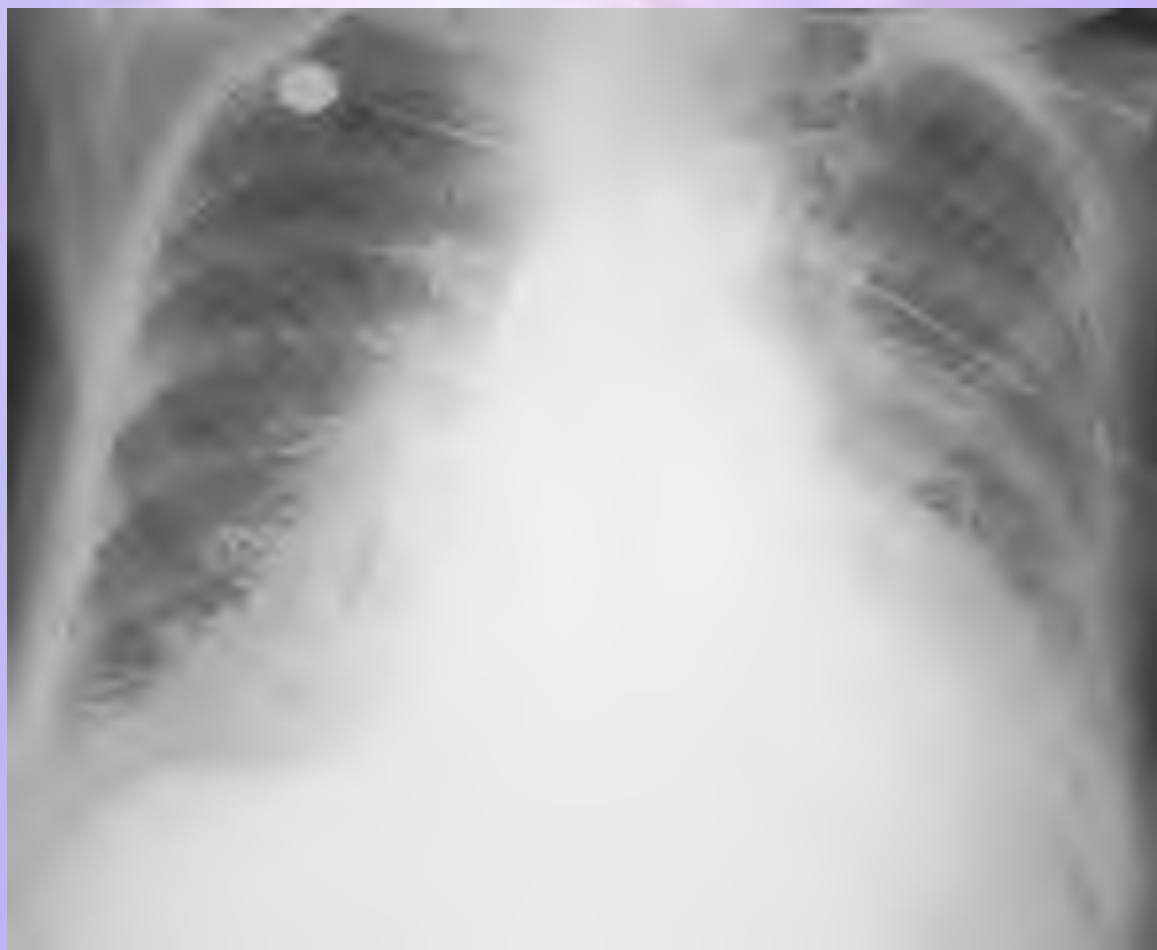Case 8

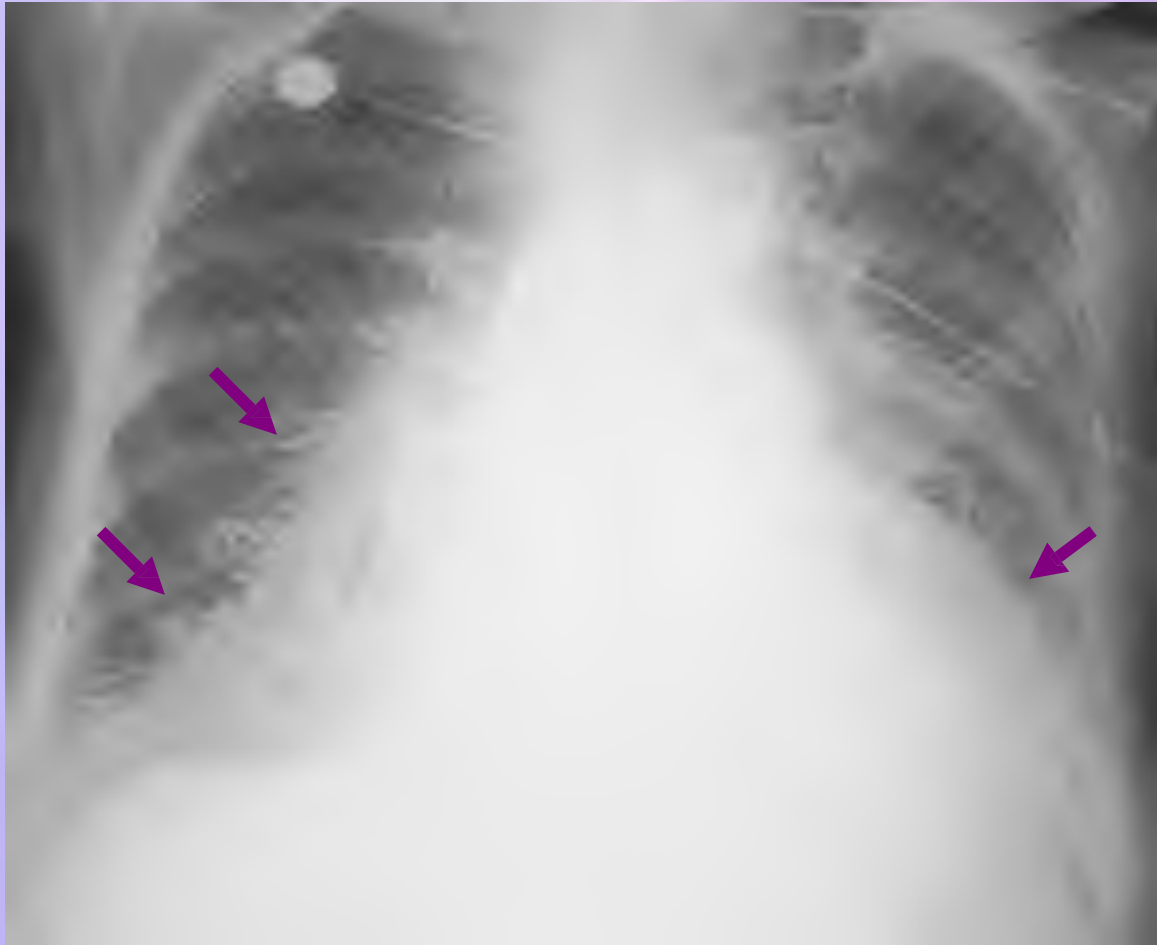




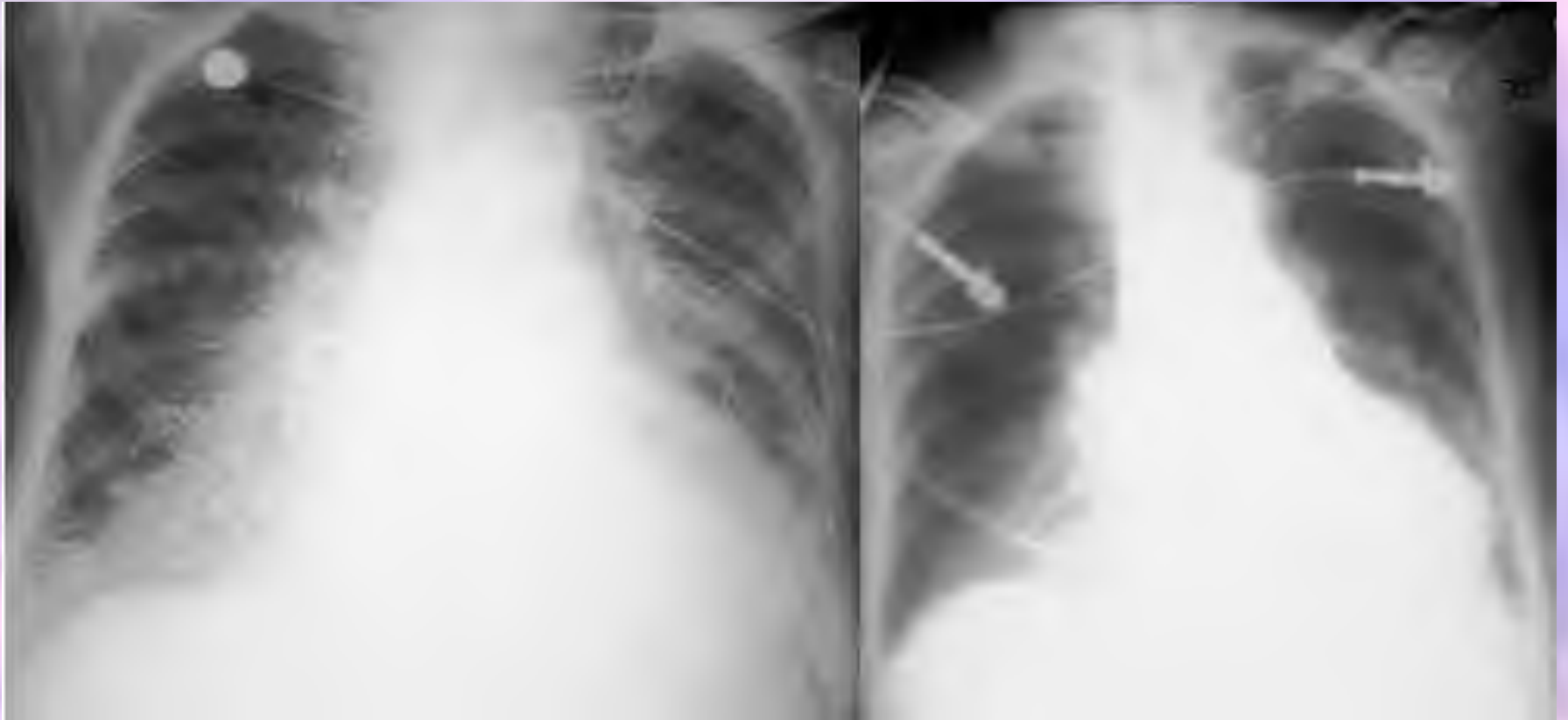Pneumonia: a large pneumonia consolidation in the right lower lobe. Knowledge of lobar and segmental anatomy is important in identifying the location of the infection

Case 9



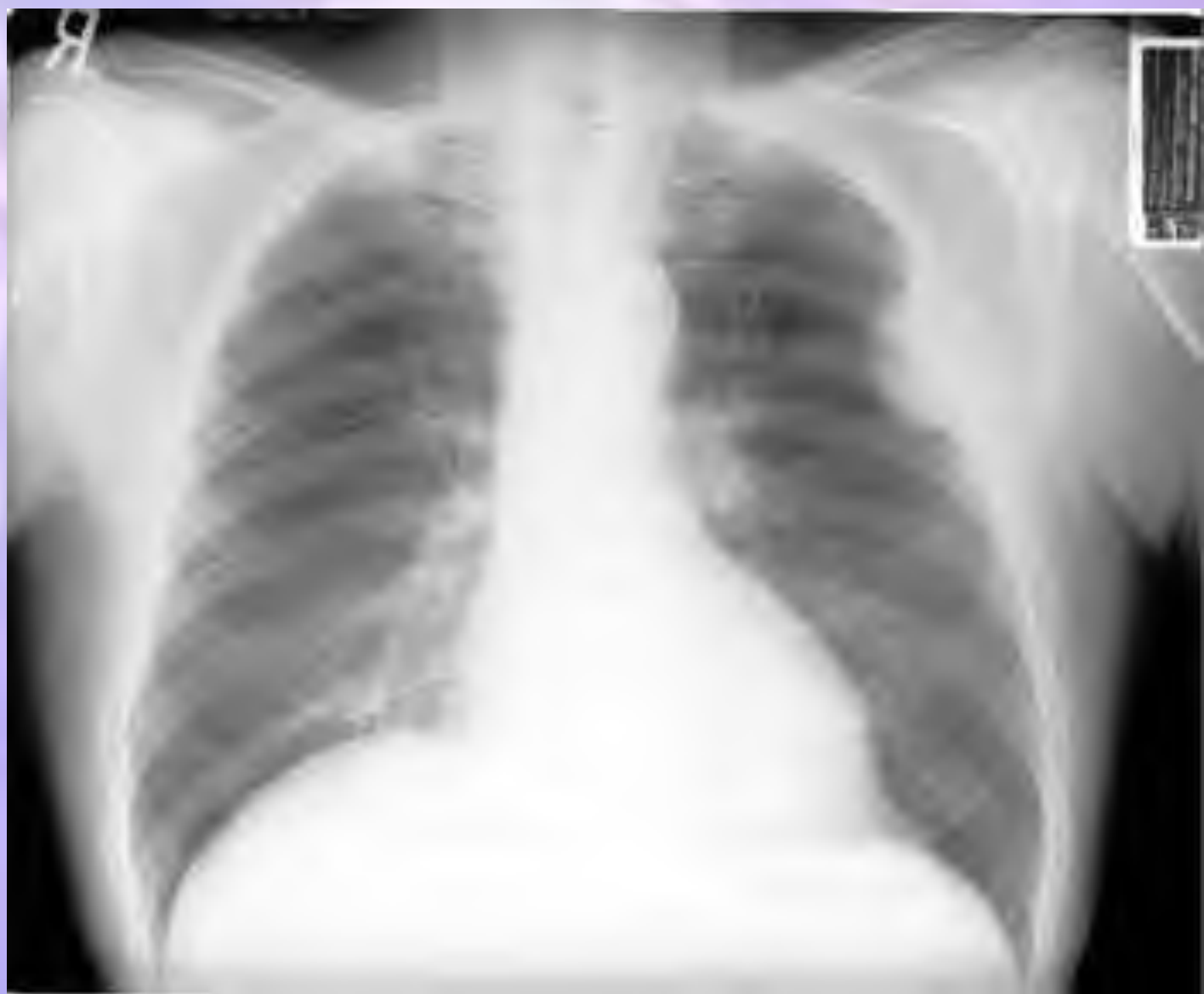

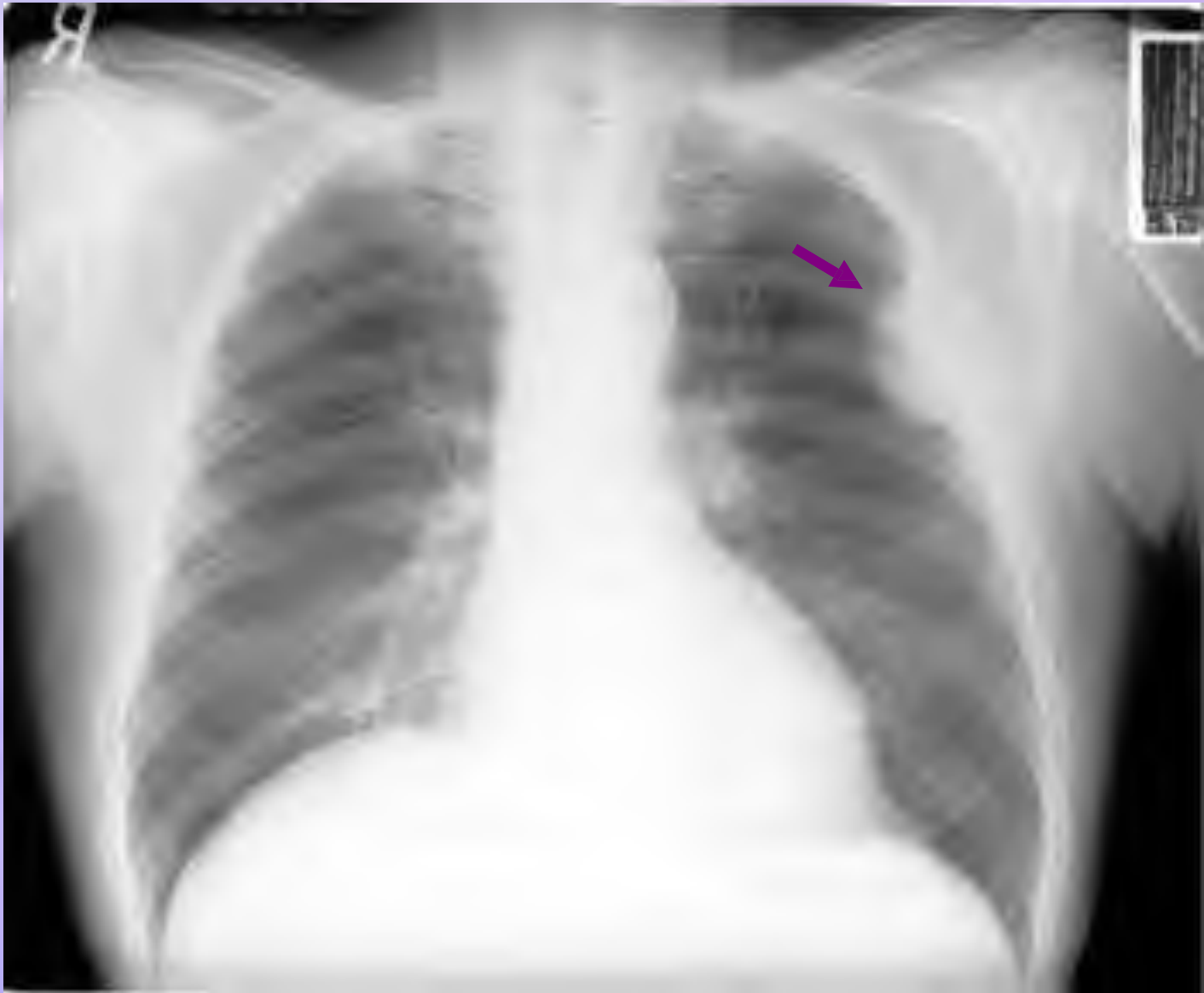CHF: a great deal of accentuated interstitial markings, Curly lines, and an enlarged heart. Normally indistinct upper lobe vessels are prominent but are also masked by interstitial edema.



24 hours after diuretic therapy

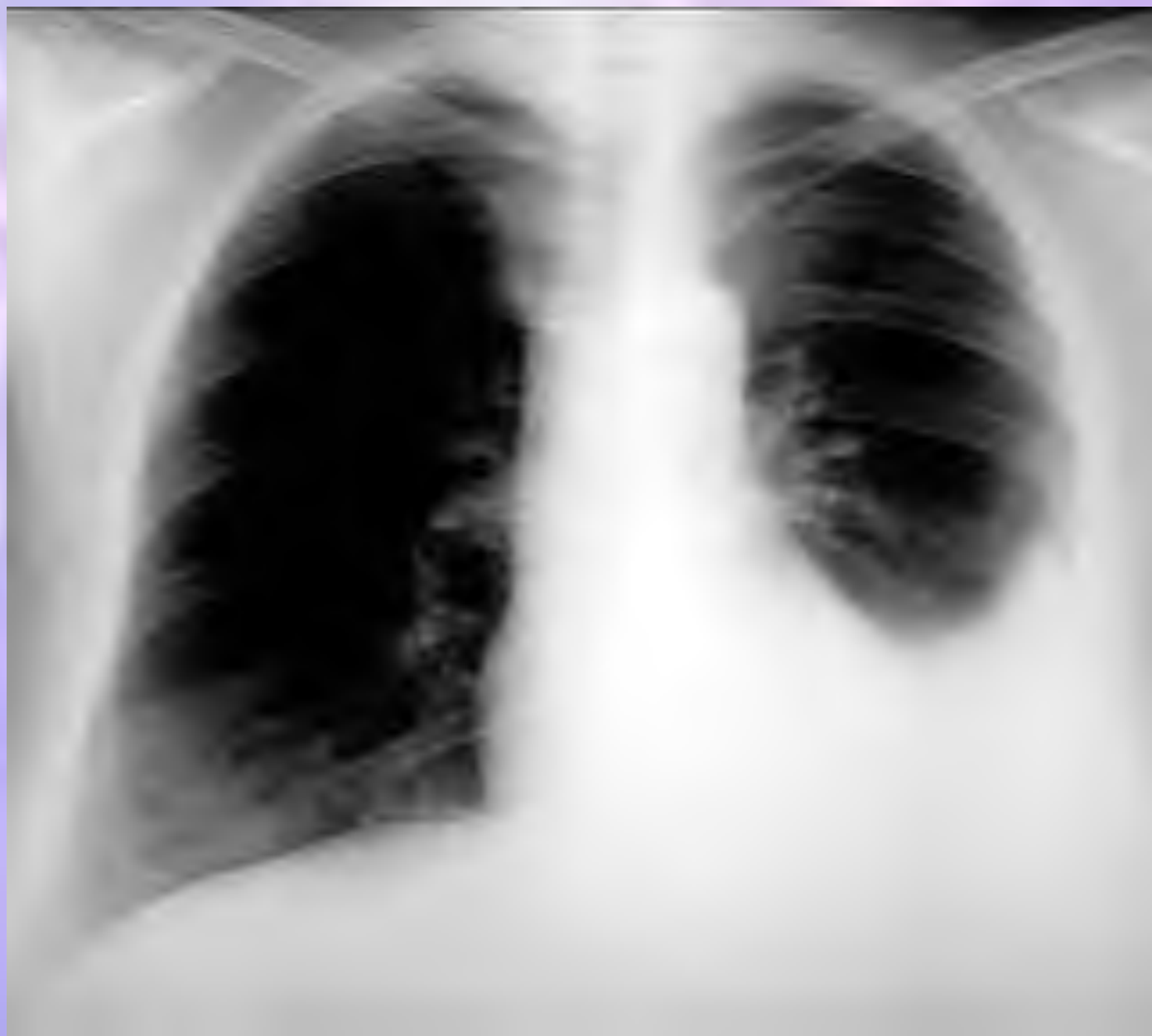Case 10

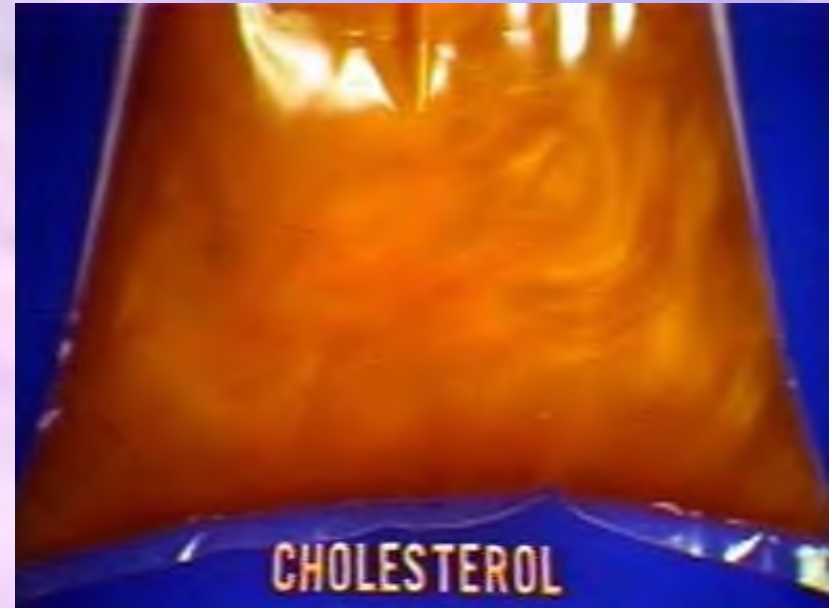
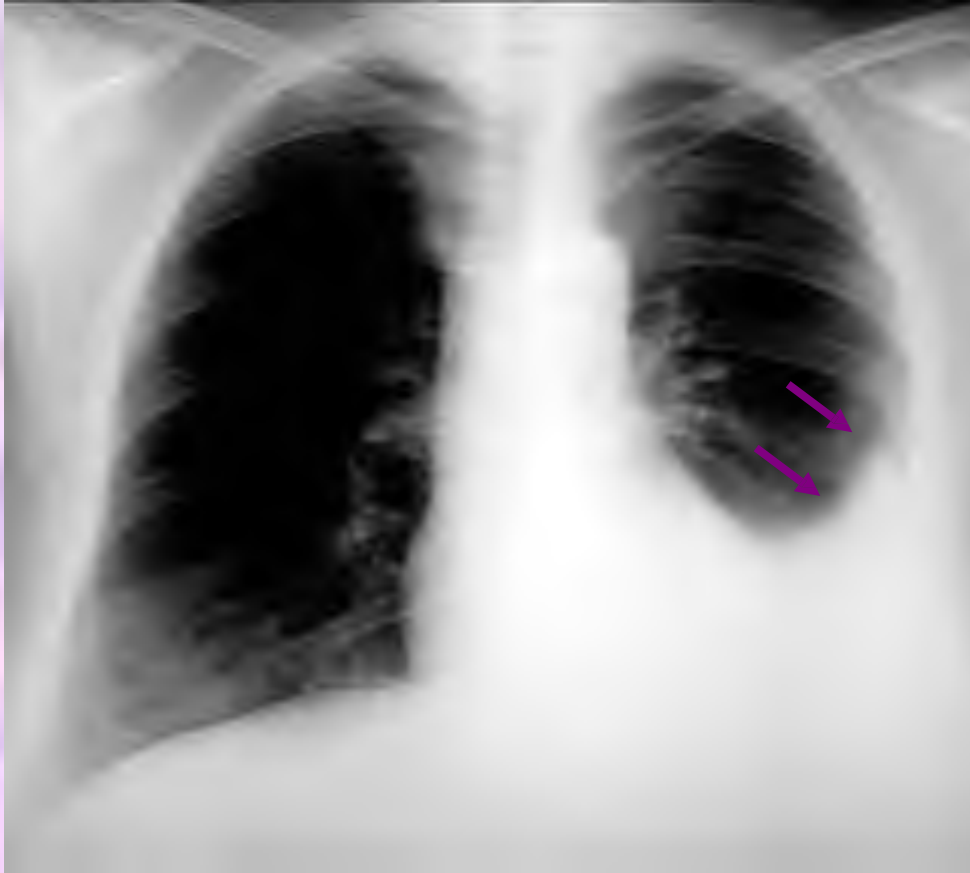


Chest wall lesion: arising off the chest wall and not the lung

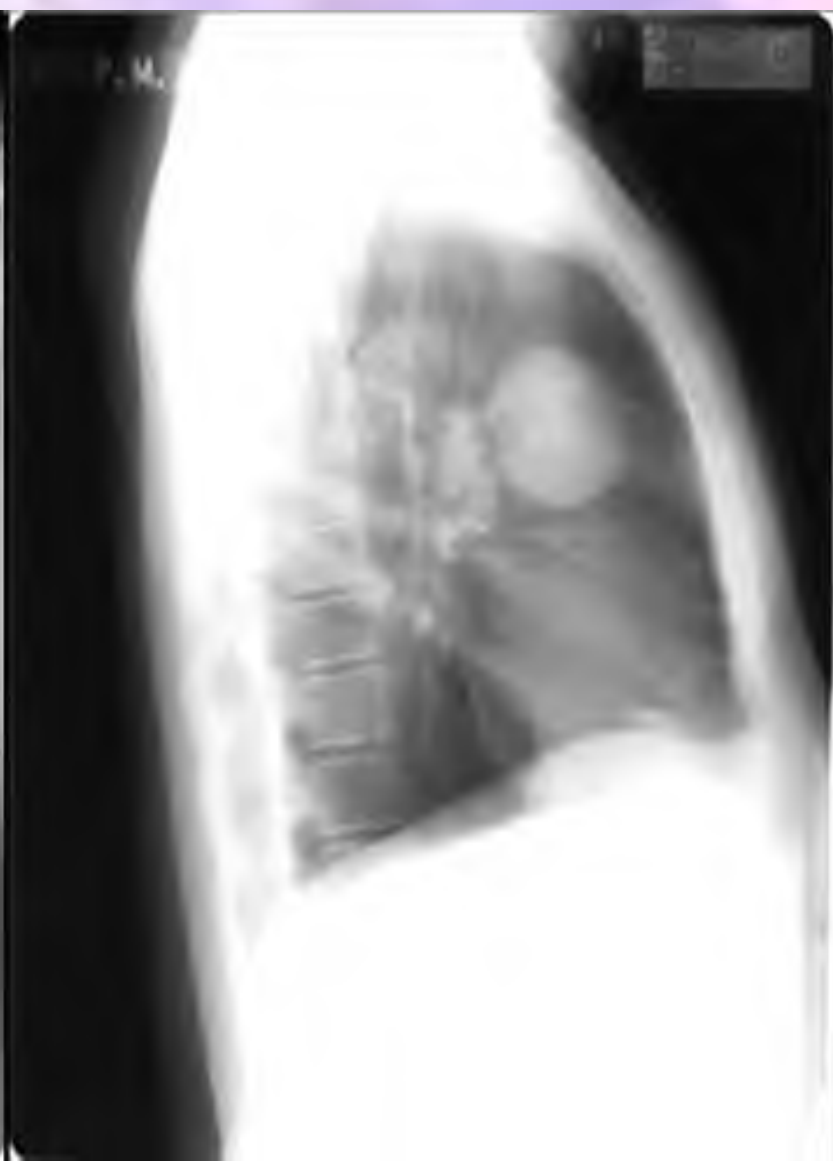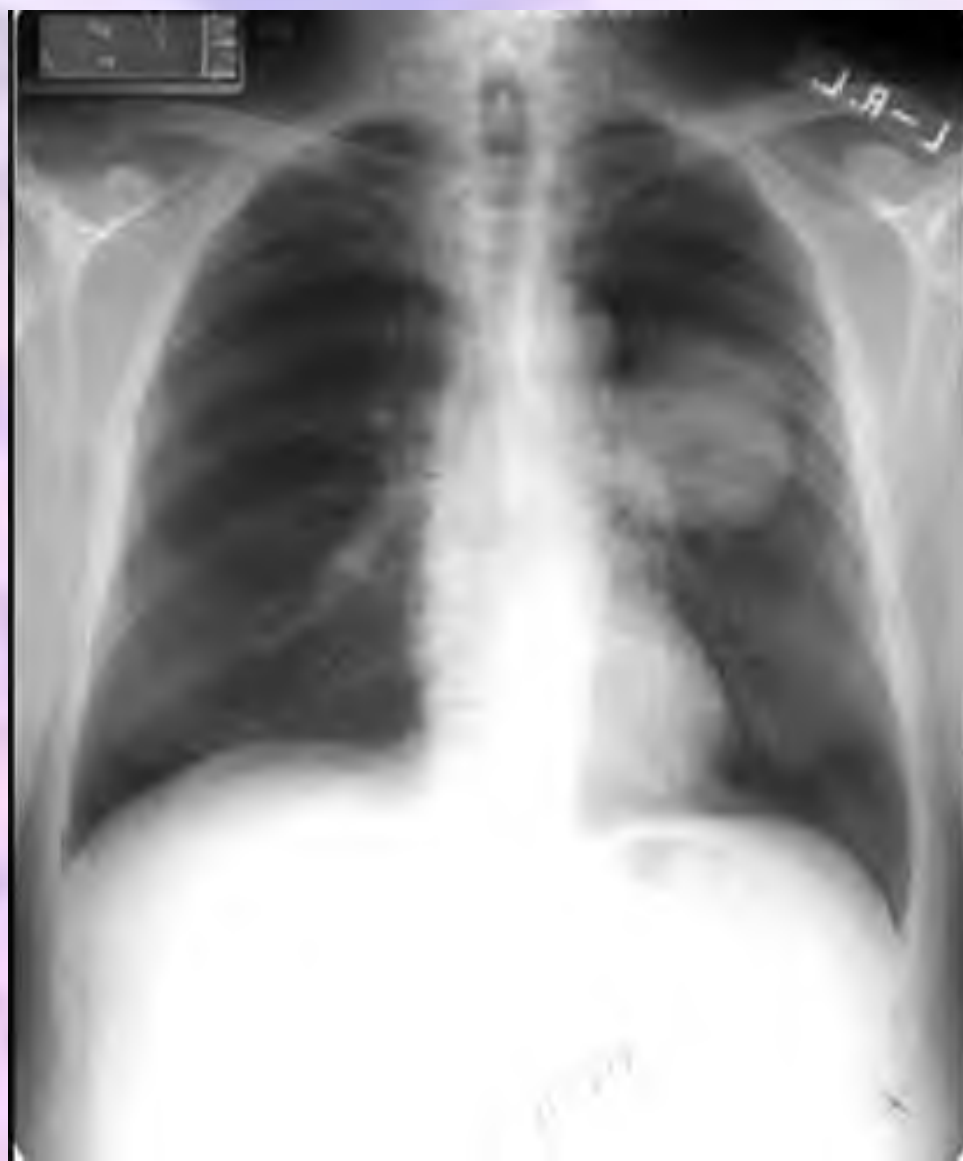Case 11

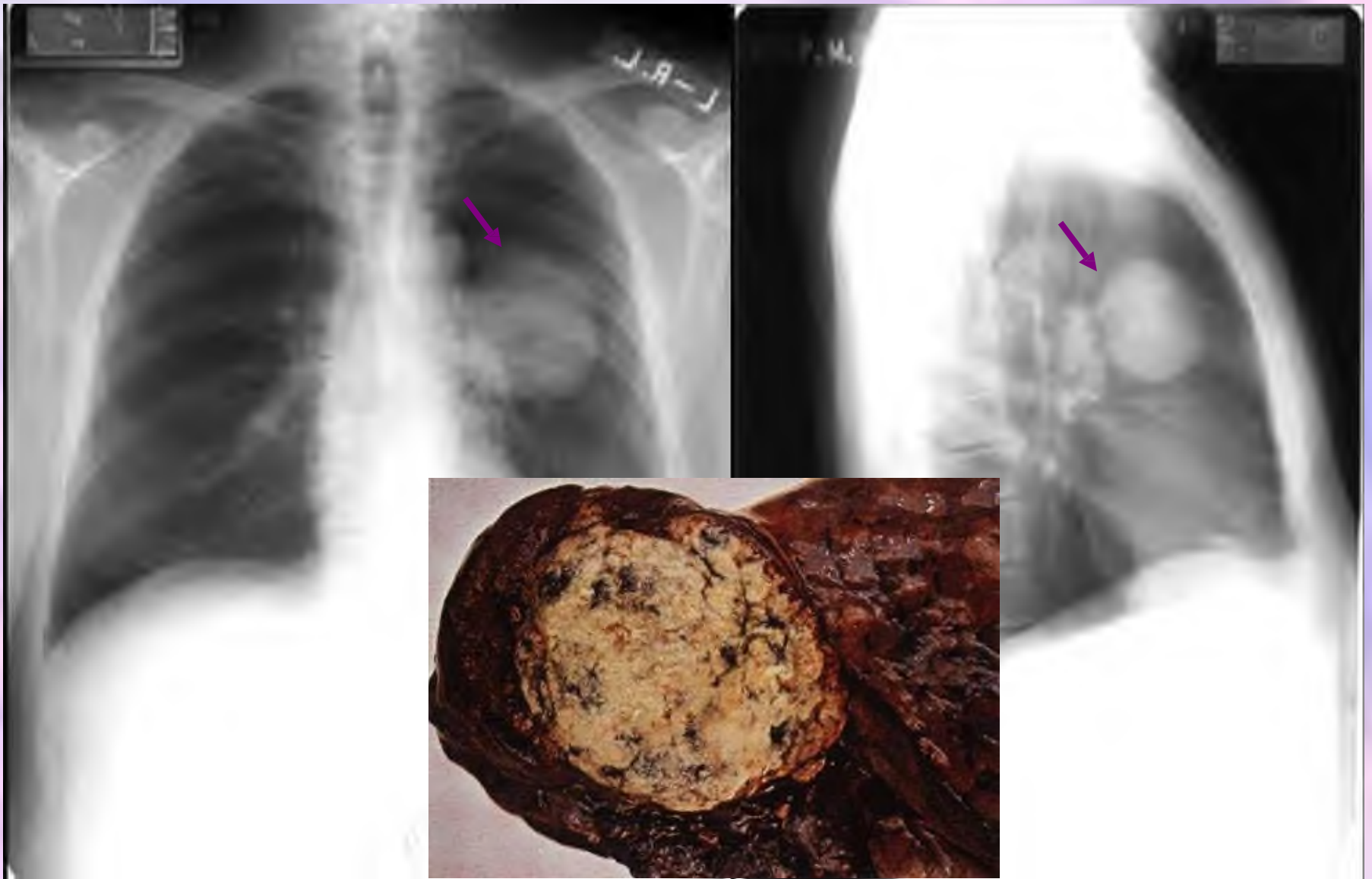




Pleural effusion: Note loss of left hemidiaphragm. Fluid drained via thoracentesis

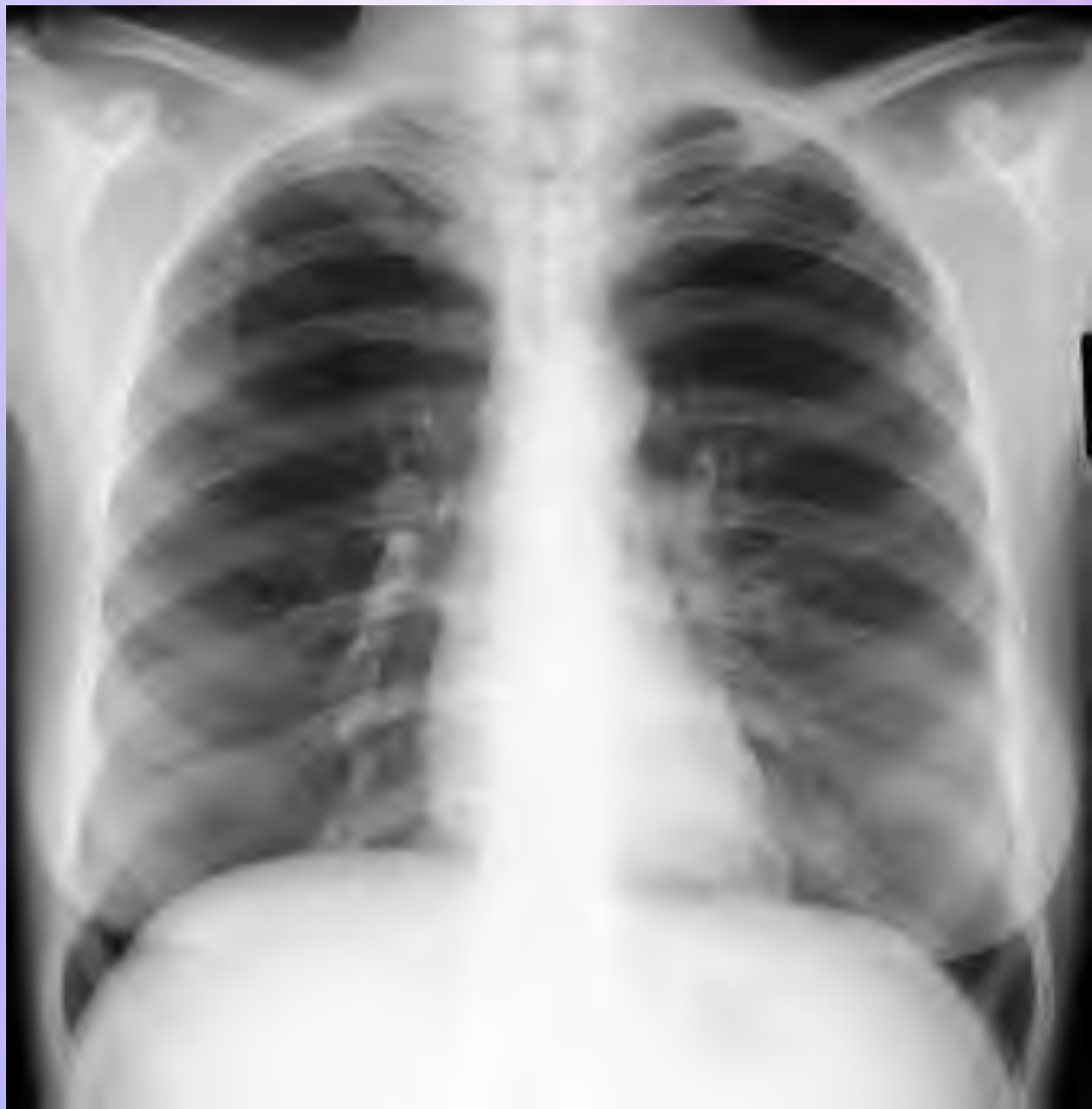Case 12

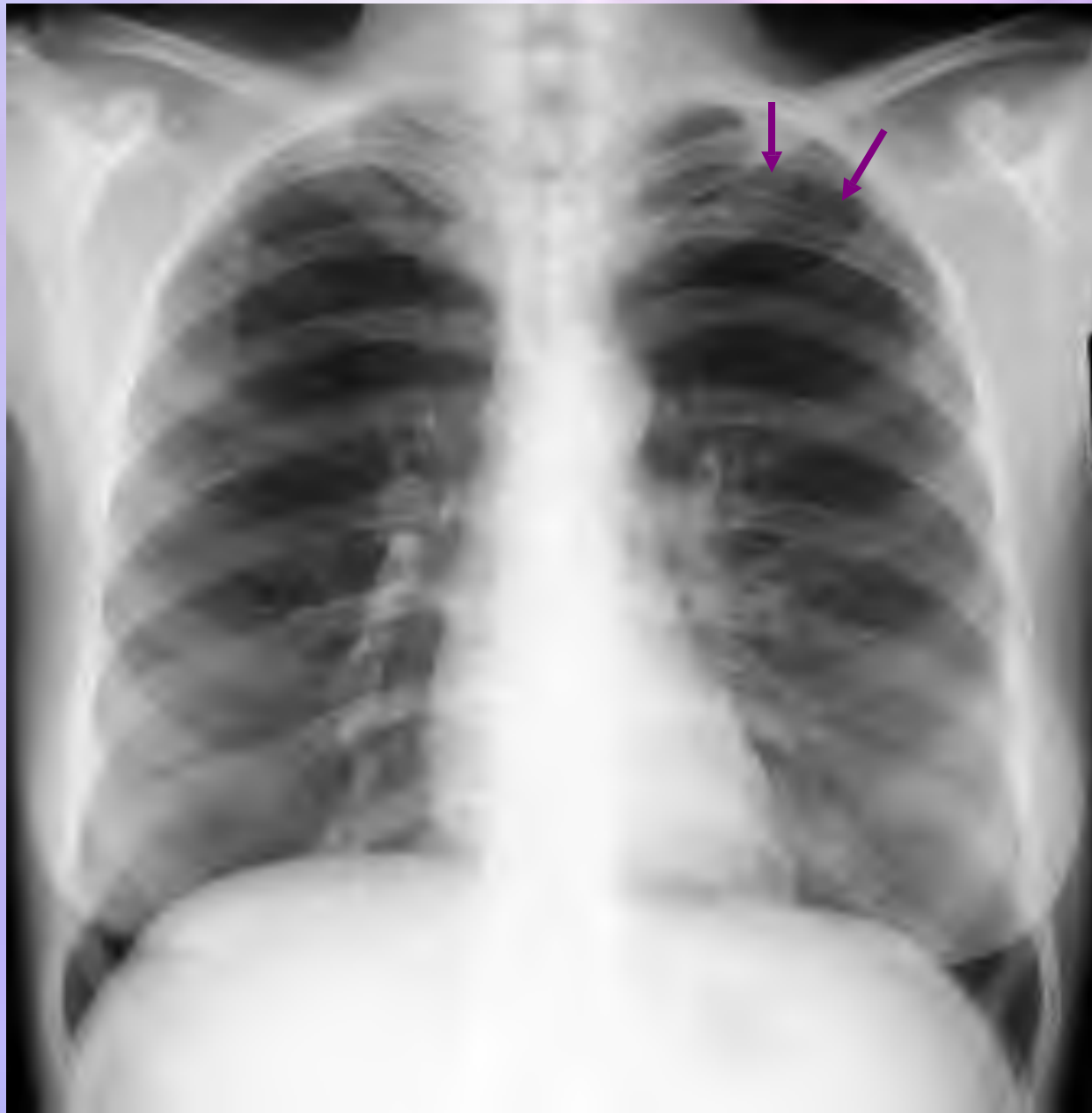



Lung Mass

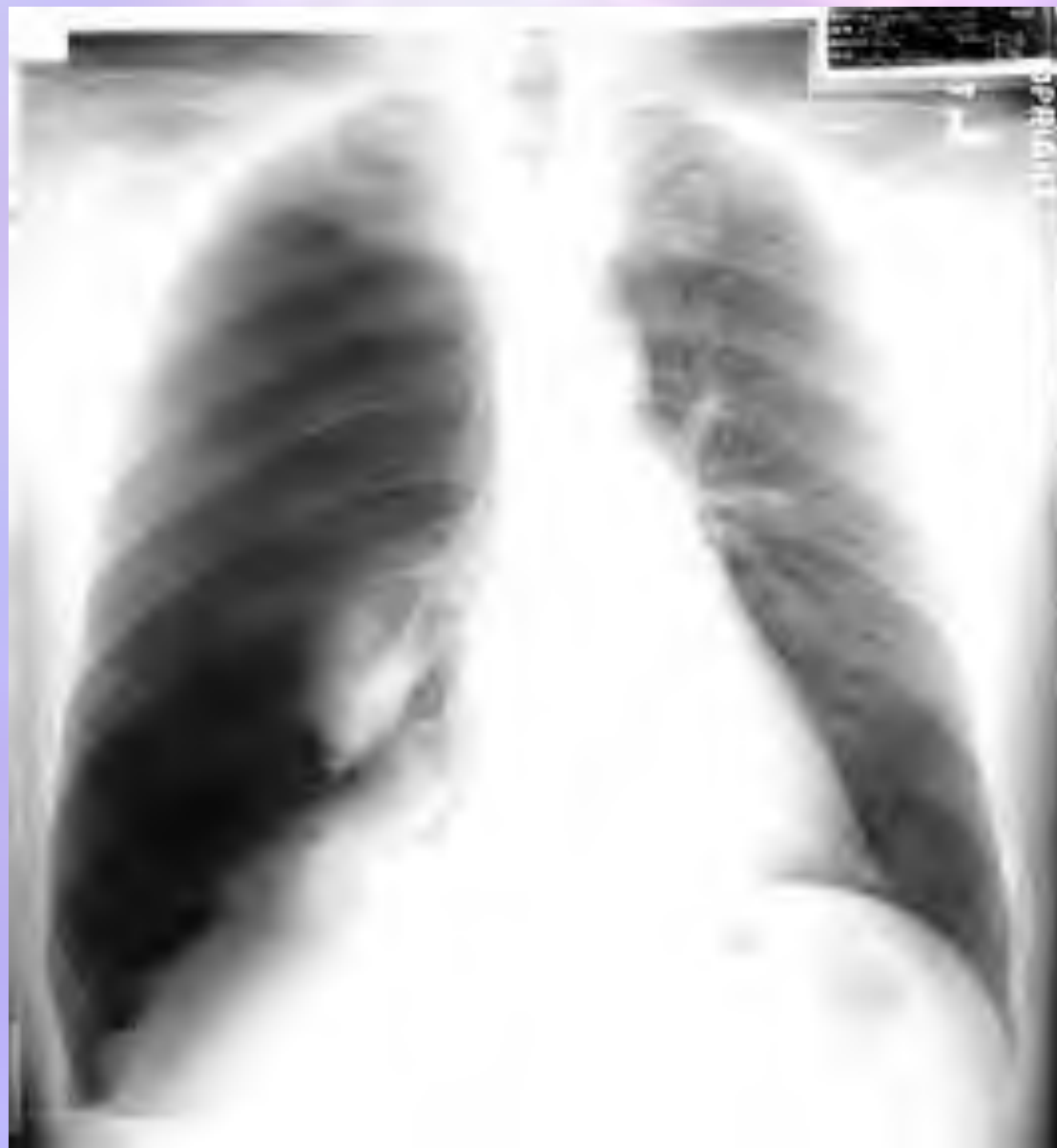Case 13

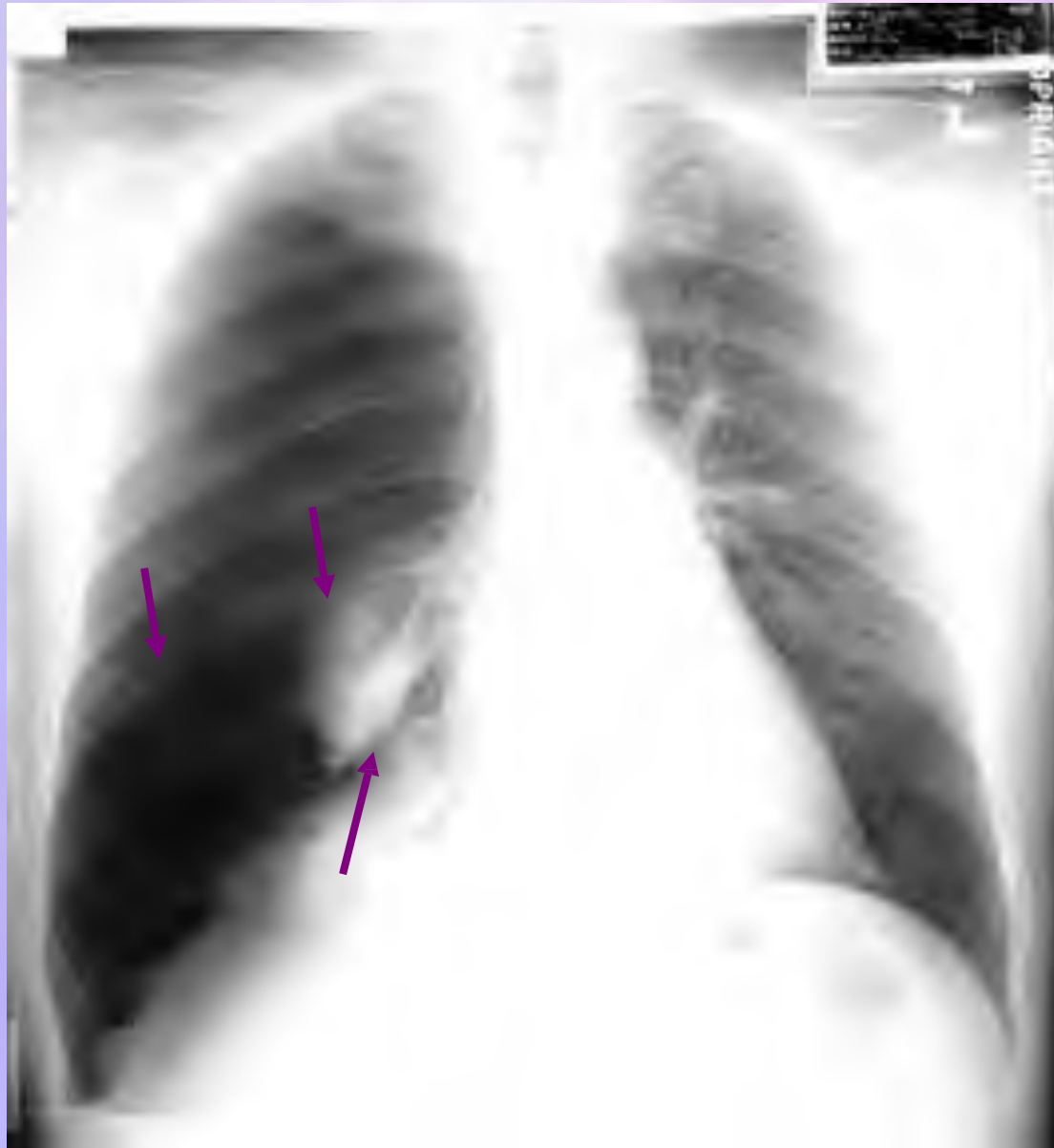



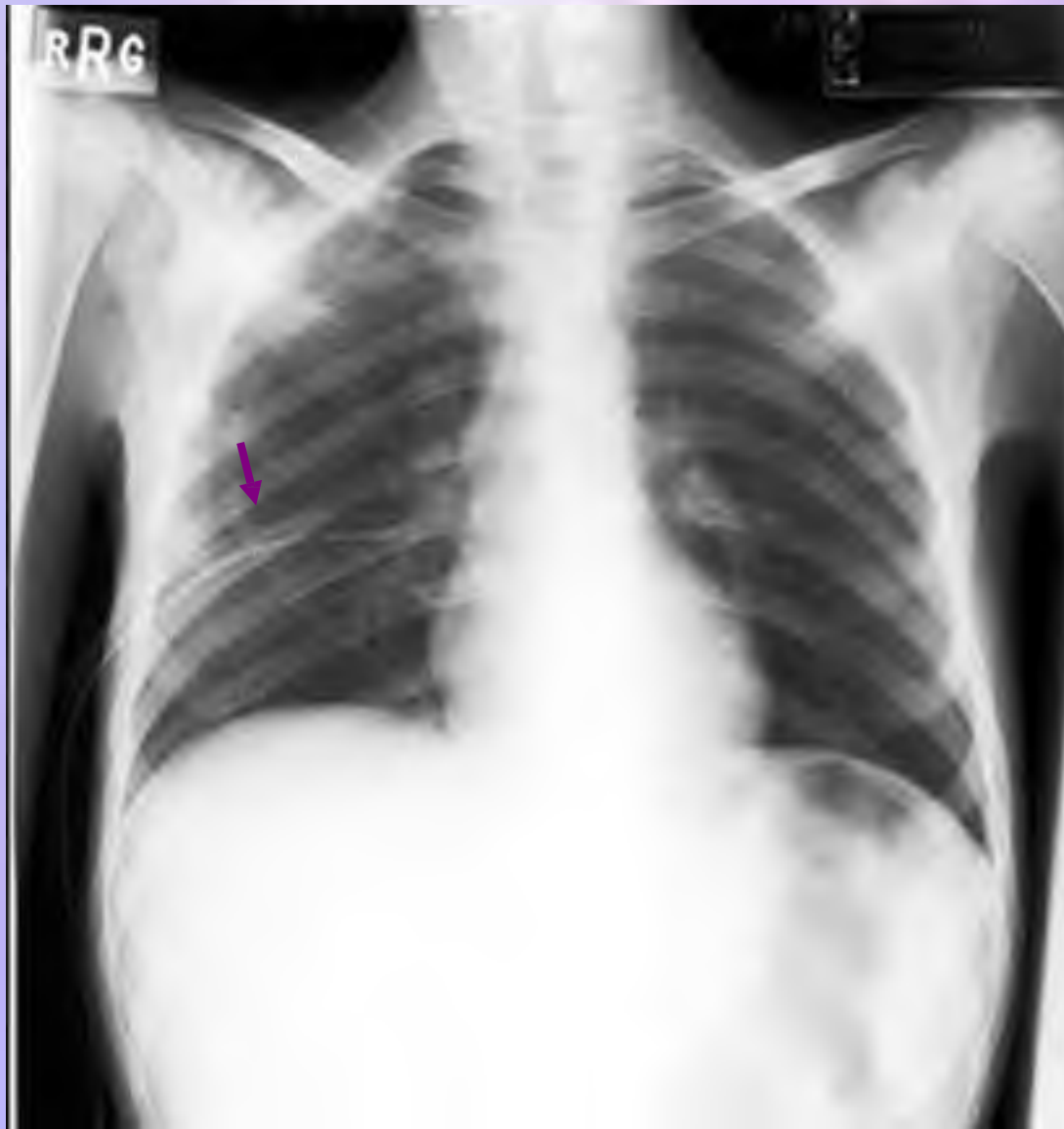Small Pneumothorax: LUL

Case 15



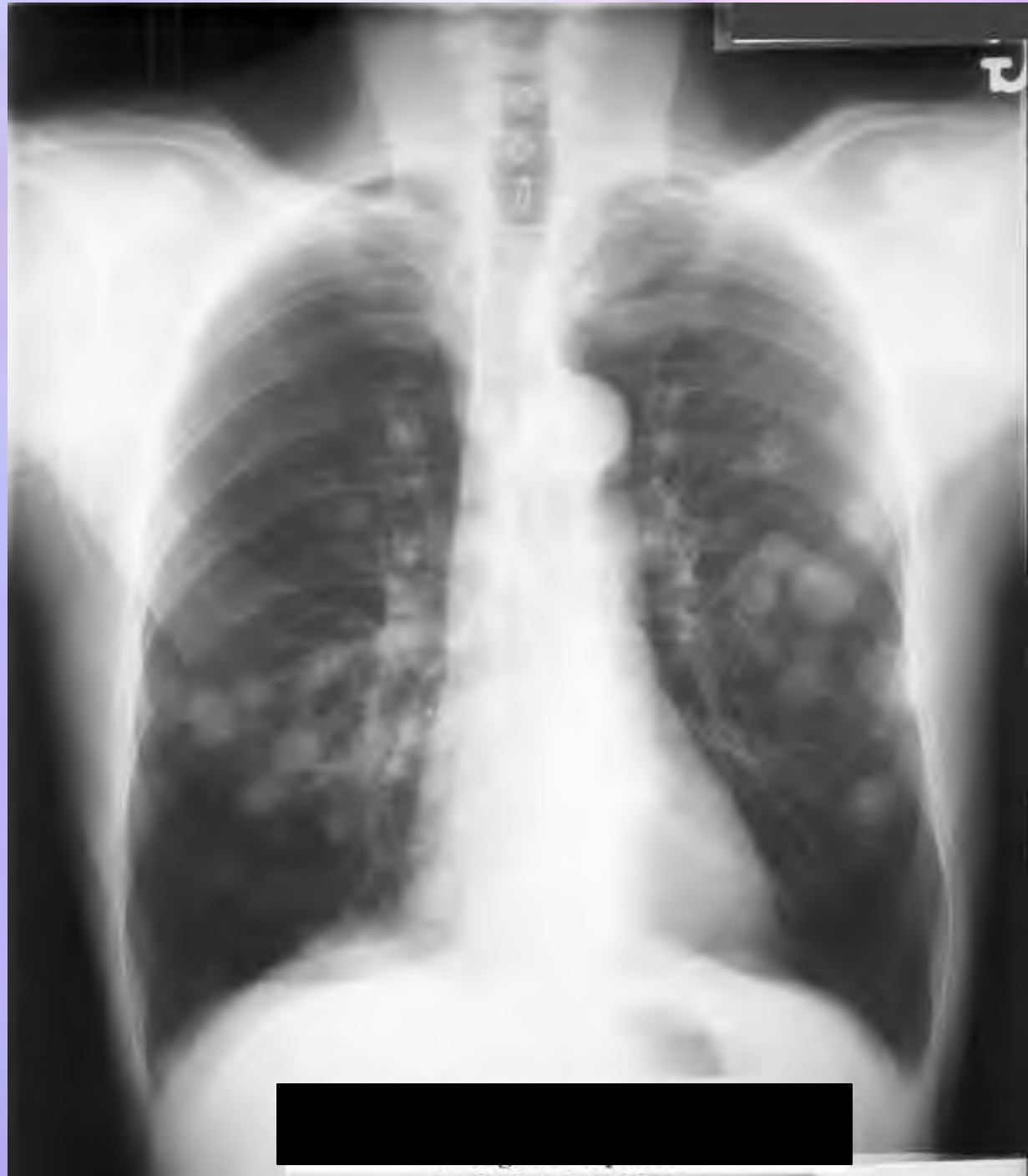

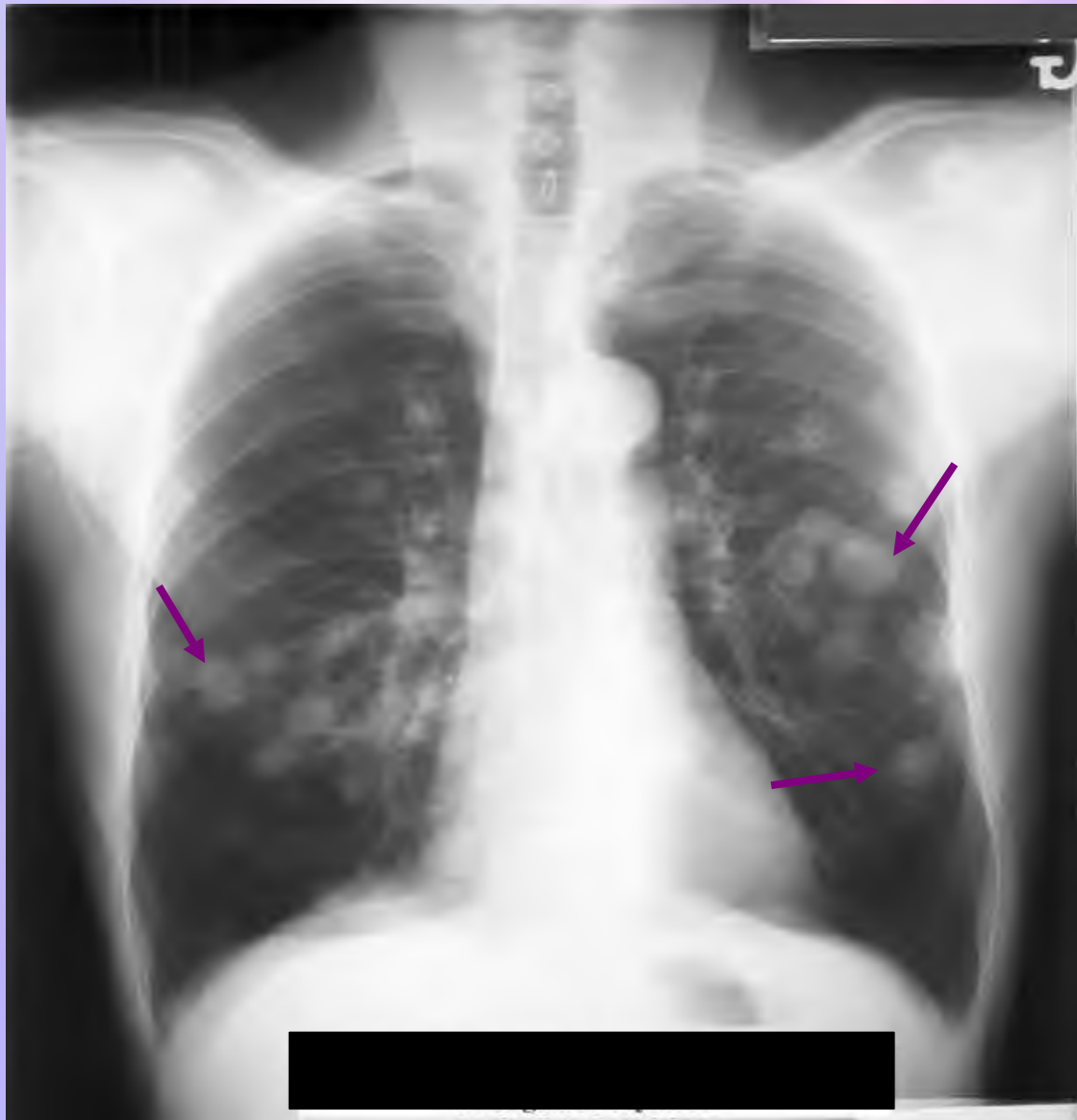Right Middle Lobe Pneumothorax: complete lobar collapse



Post chest tube insertion and re-expansion

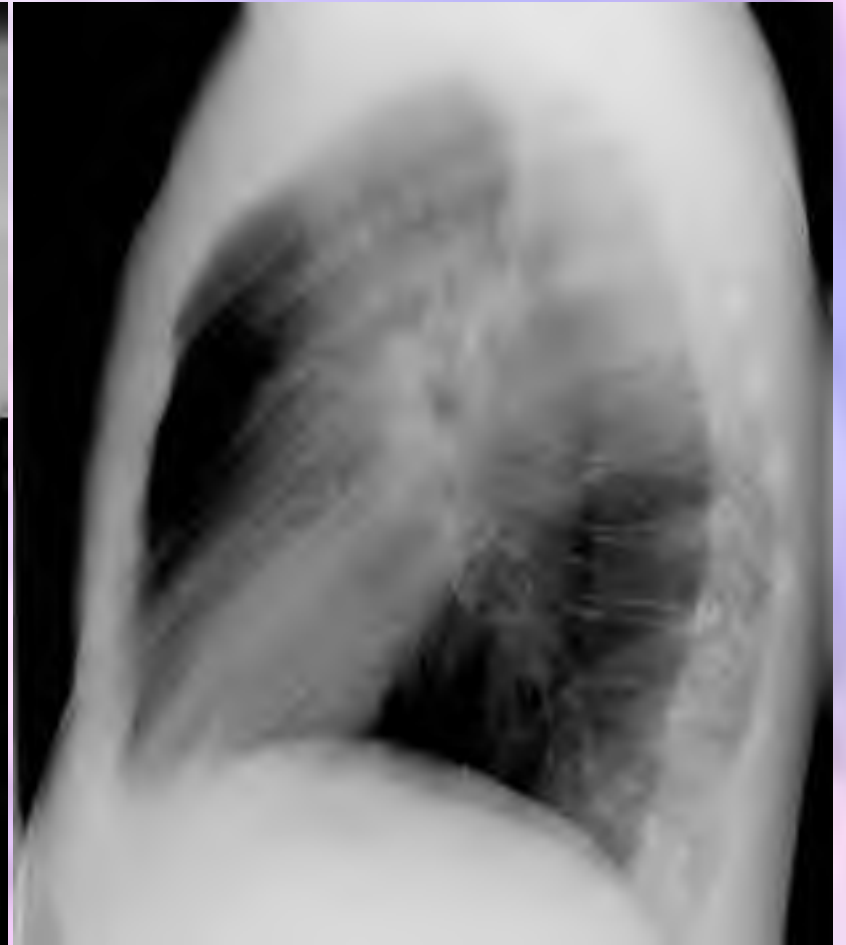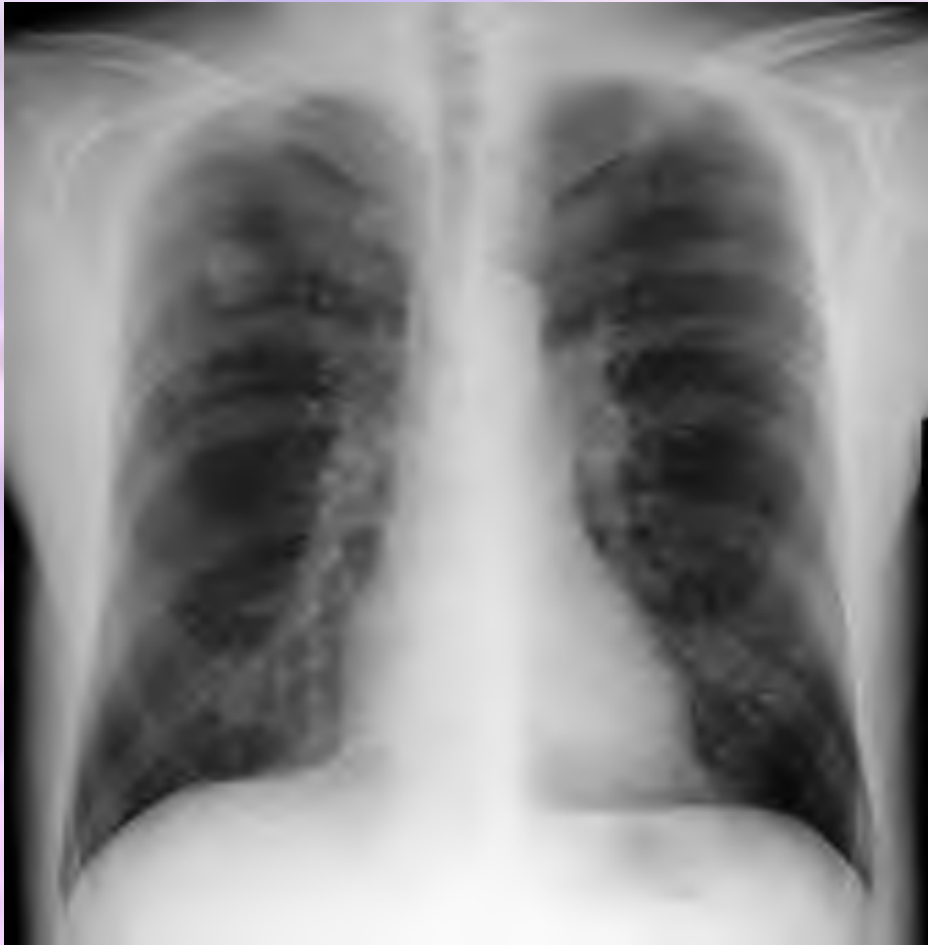Case 16

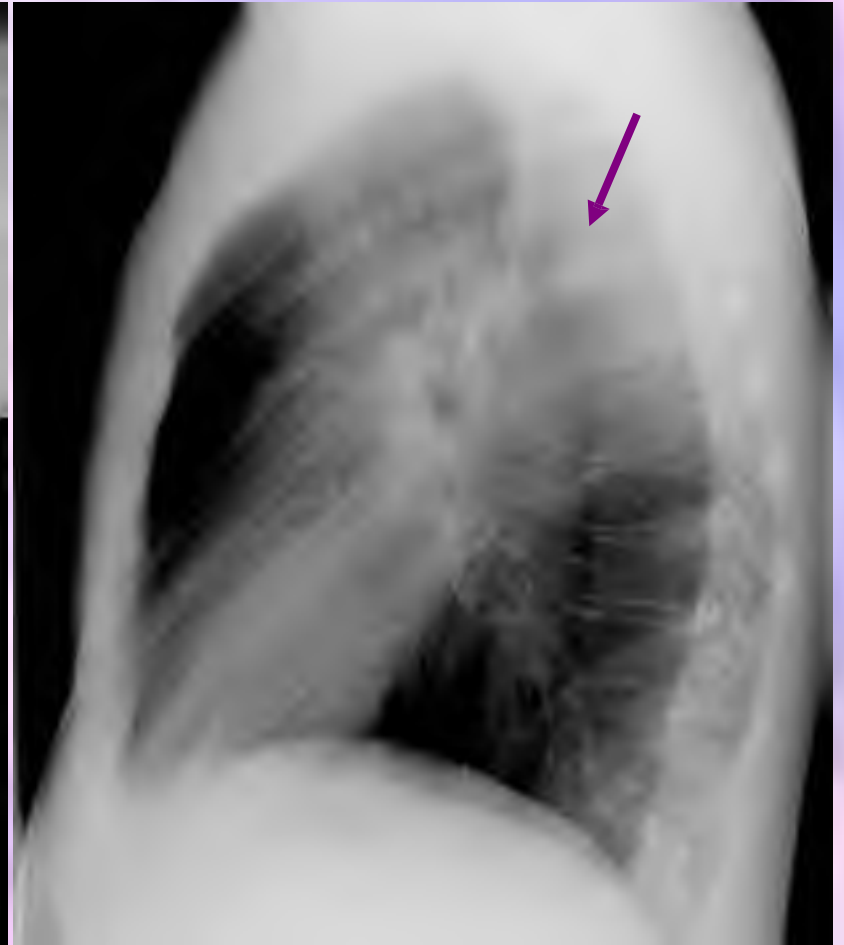
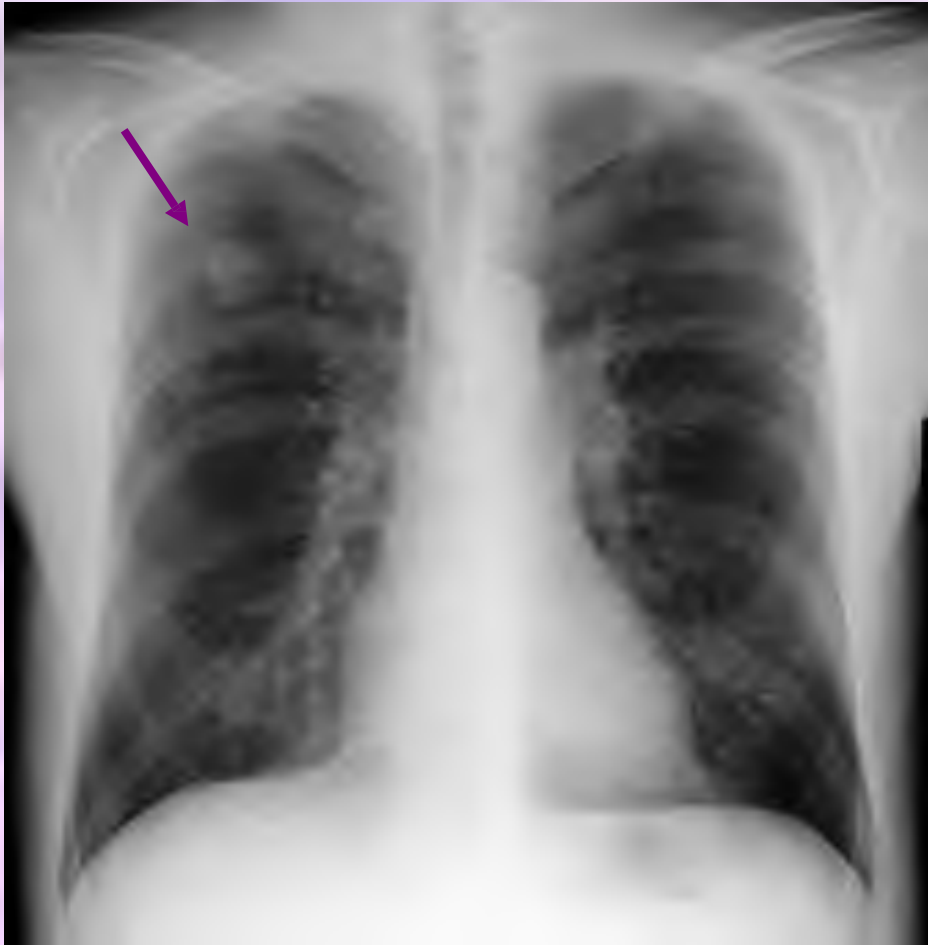



Metastatic Lung Cancer: multiple nodules seen

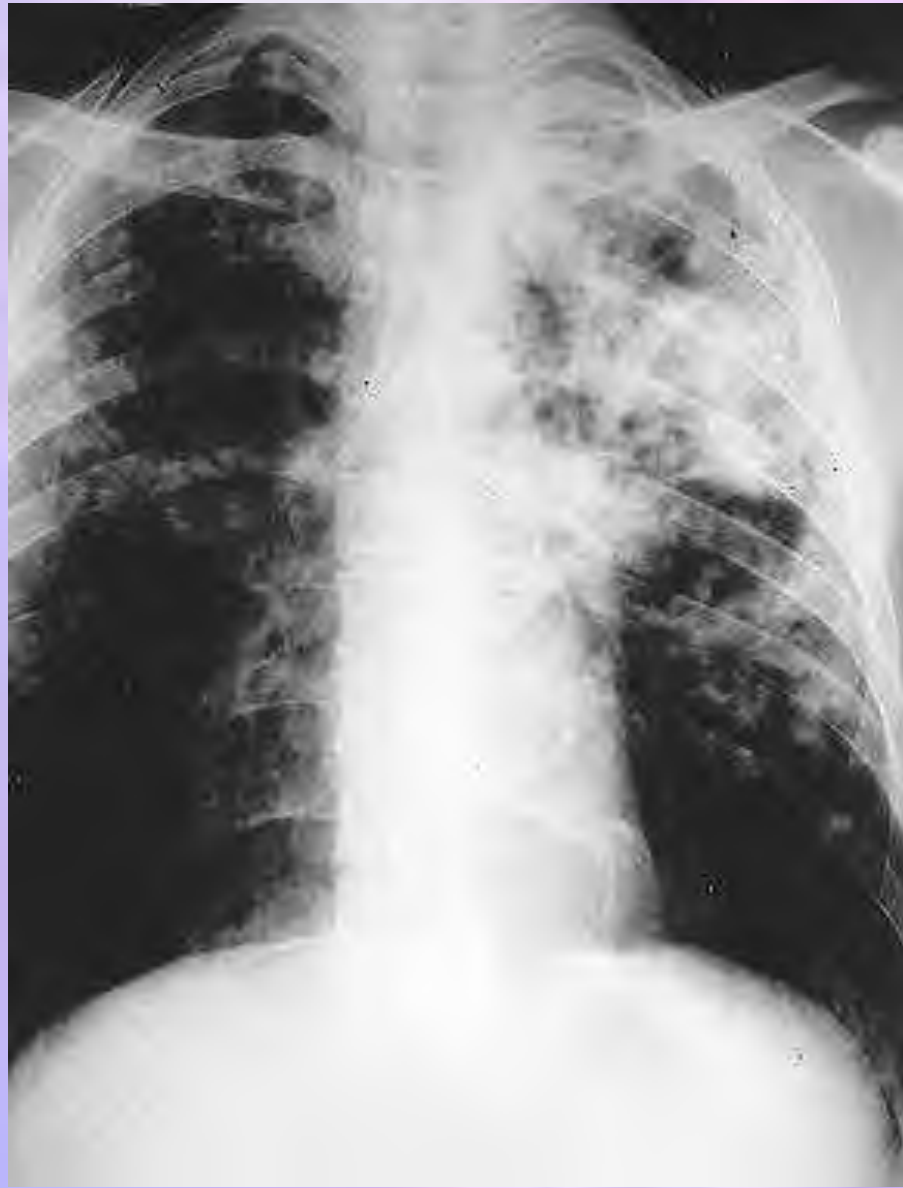Case 17

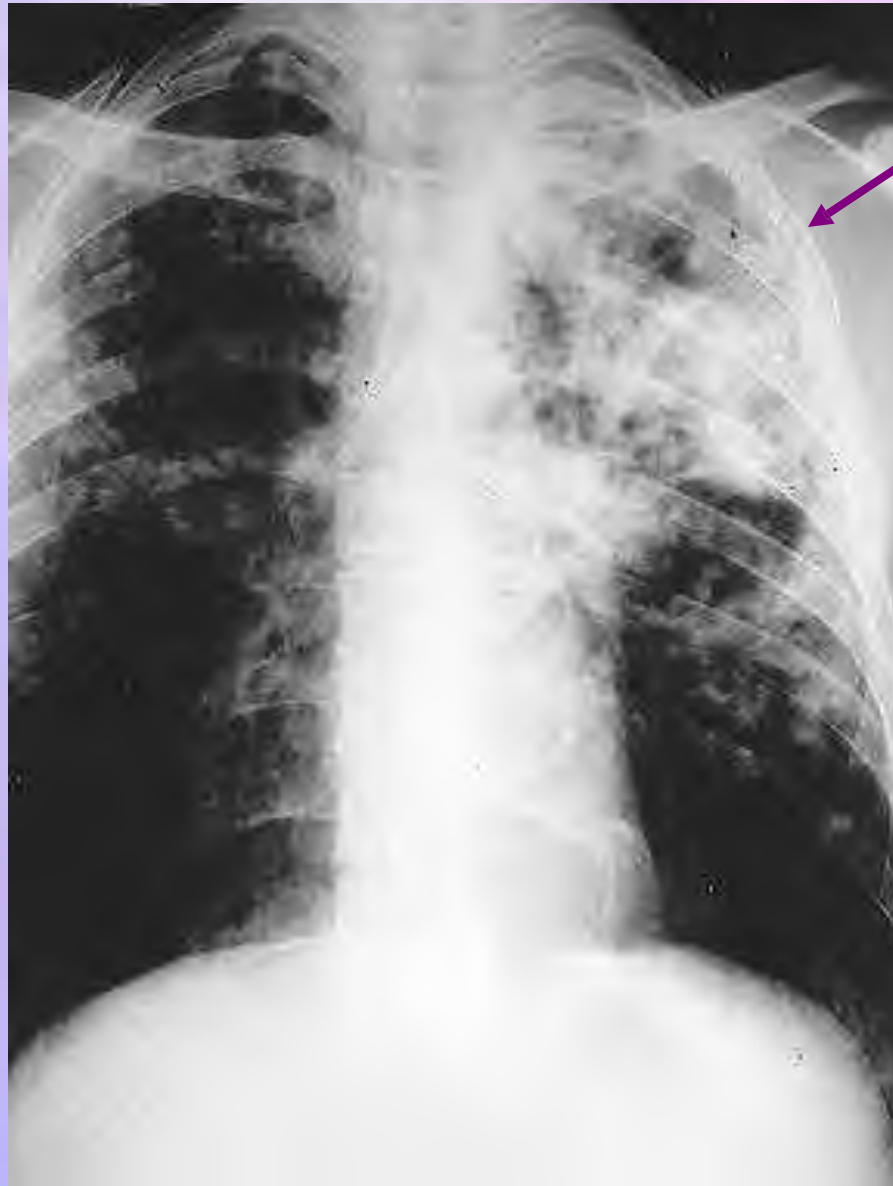




Right upper lower lobe pulmonary nodule

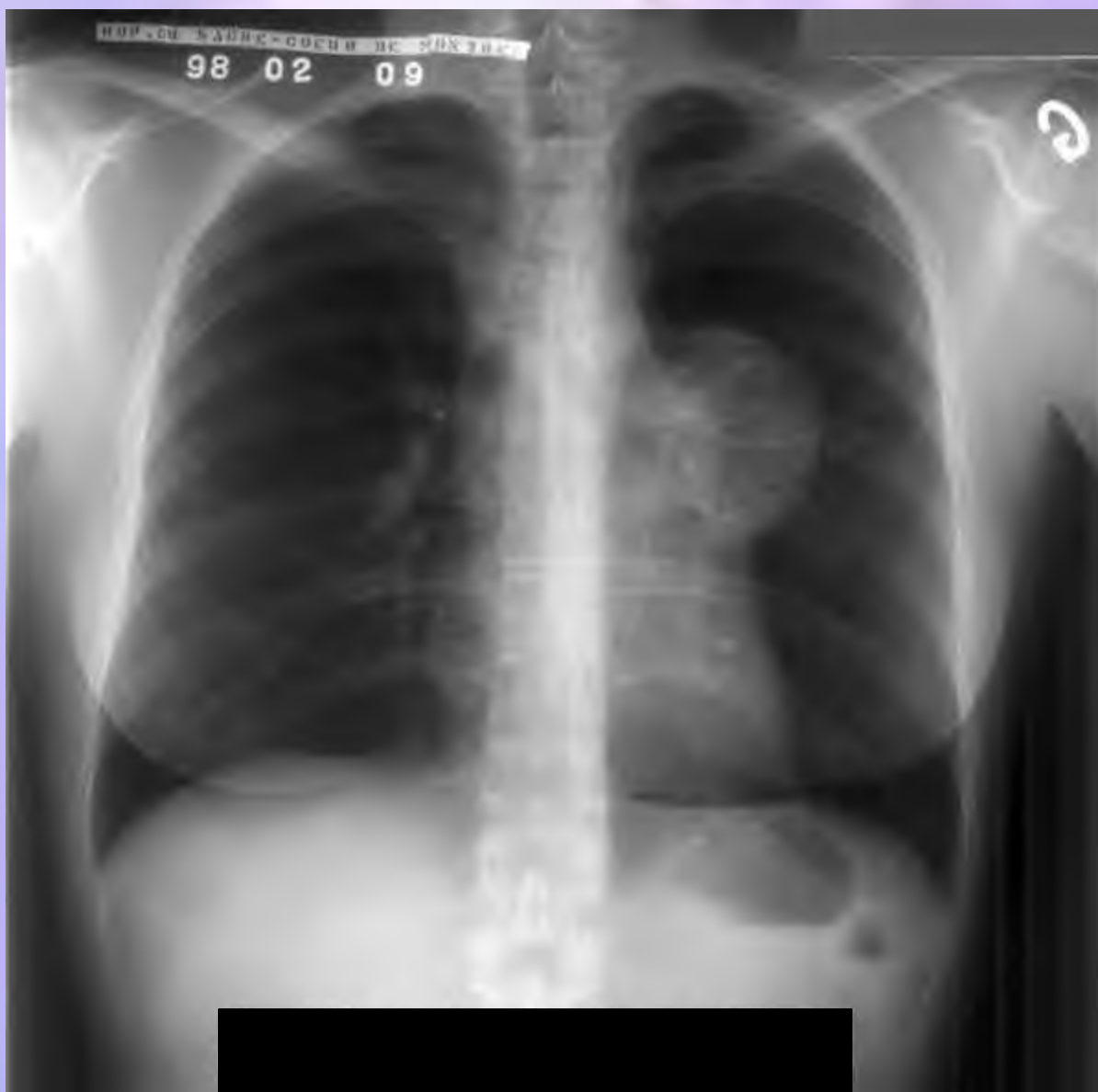
Case 18

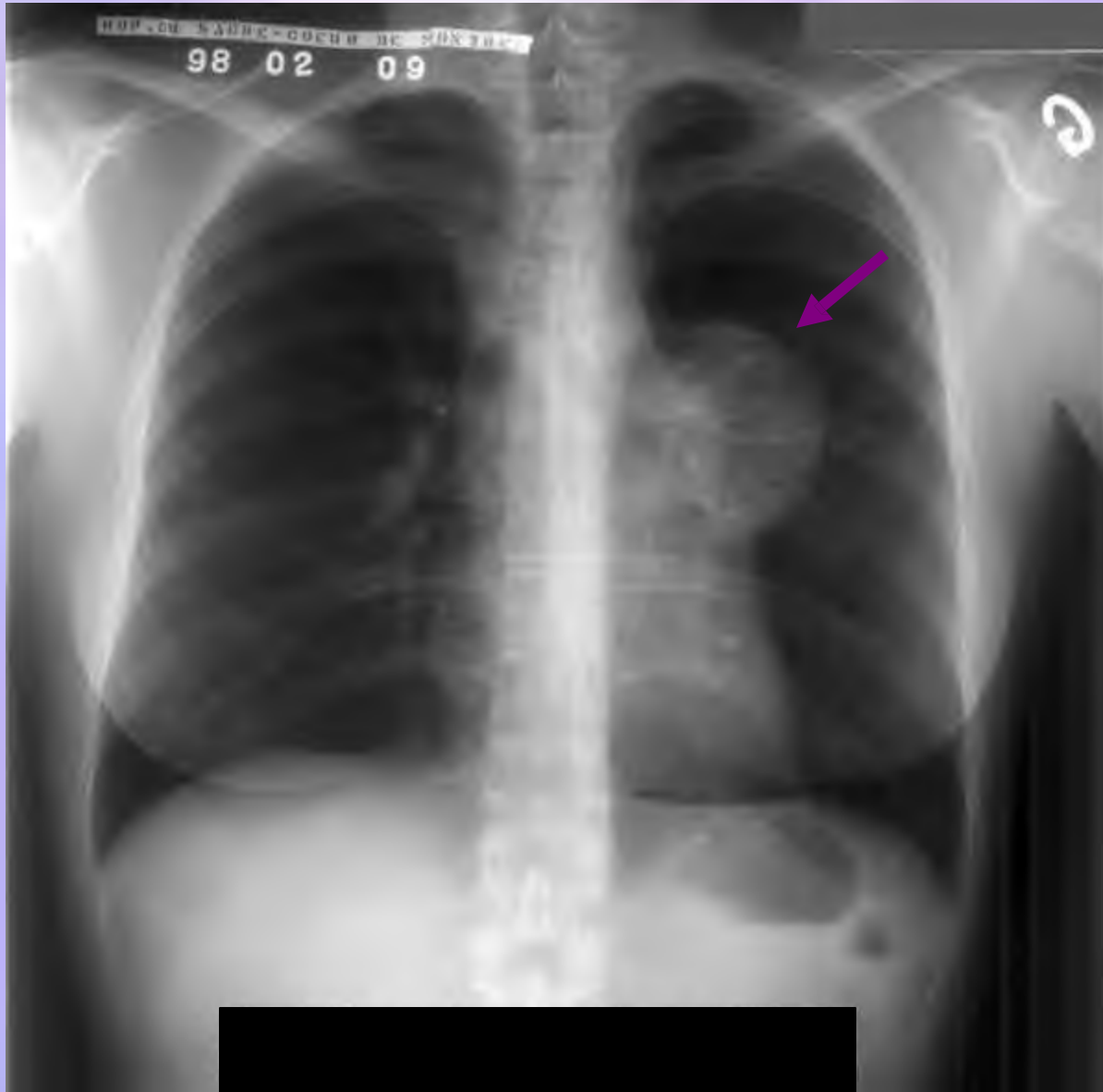




Tuberculosis

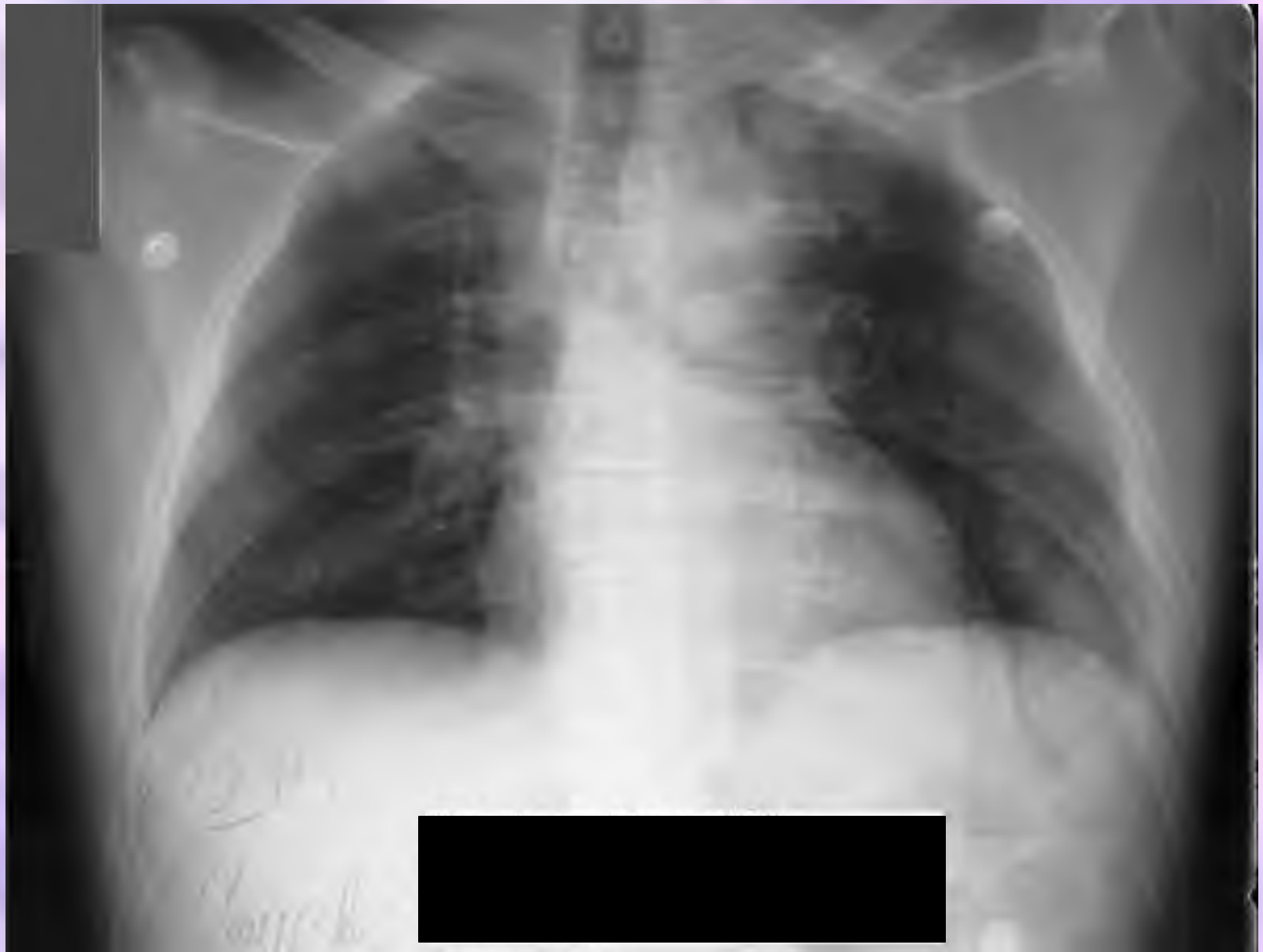Case 19

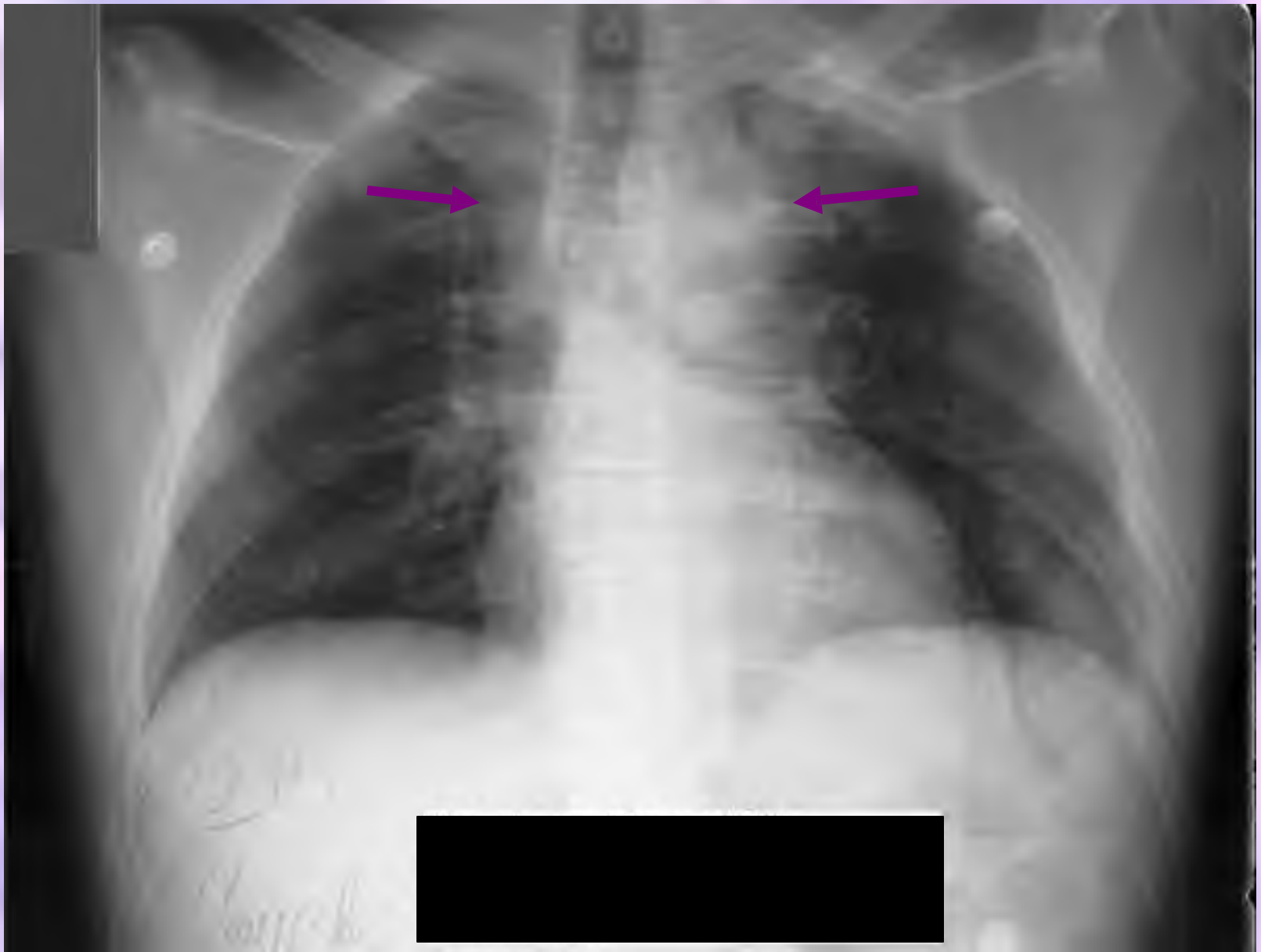



Perihilar mass: Hodgkin's disease

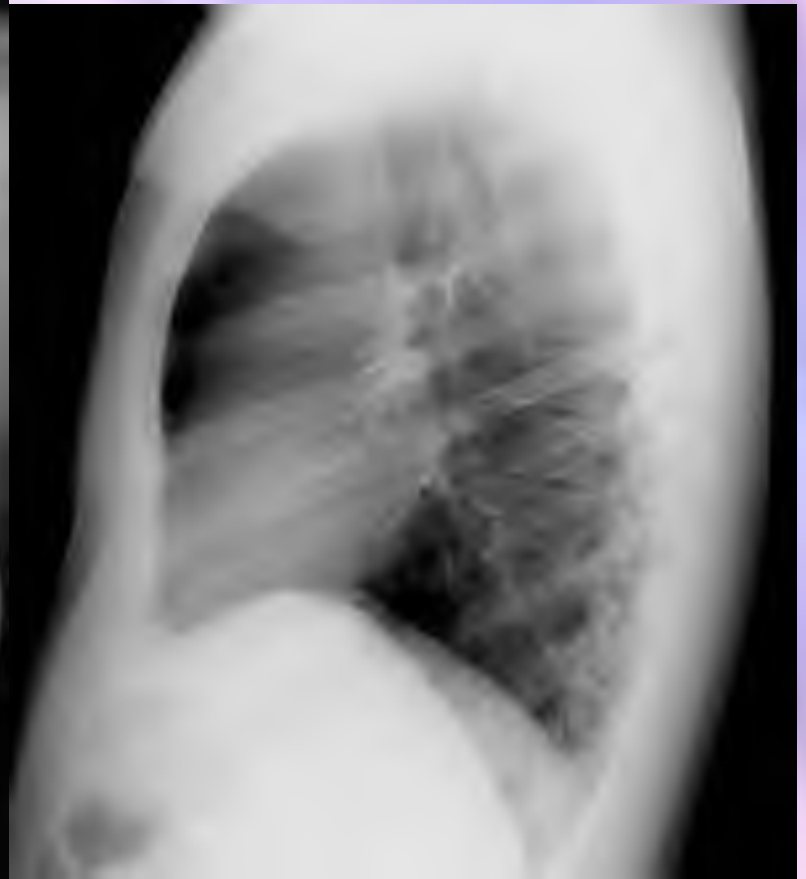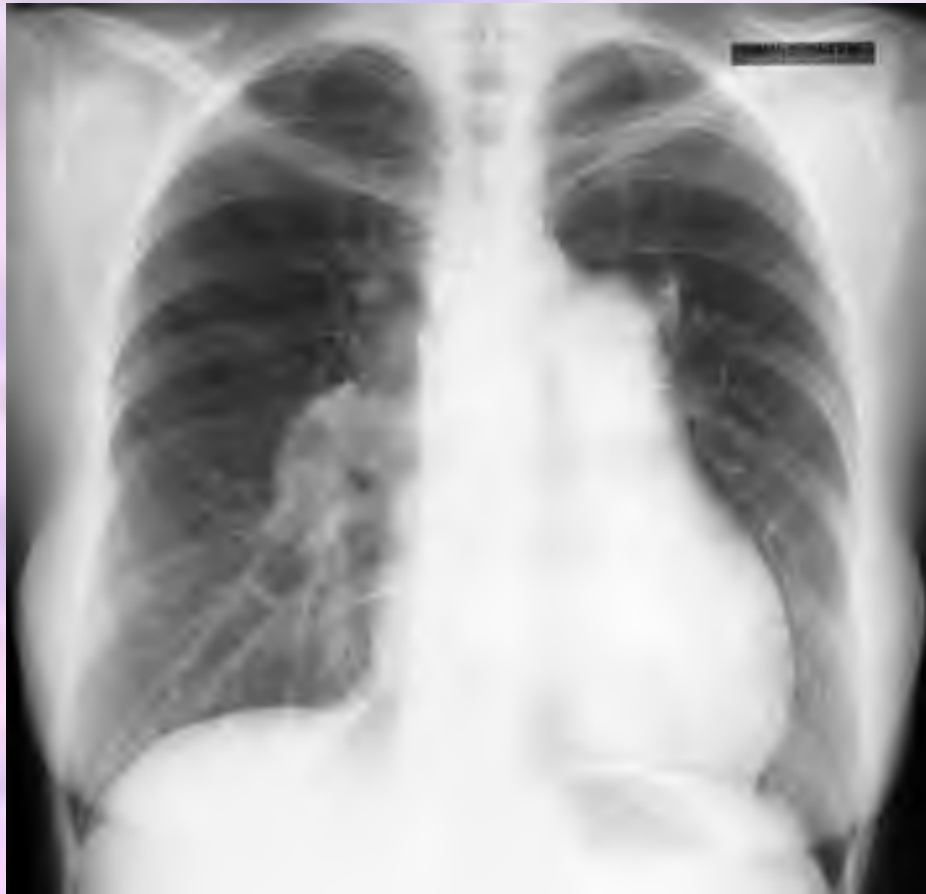Case 20

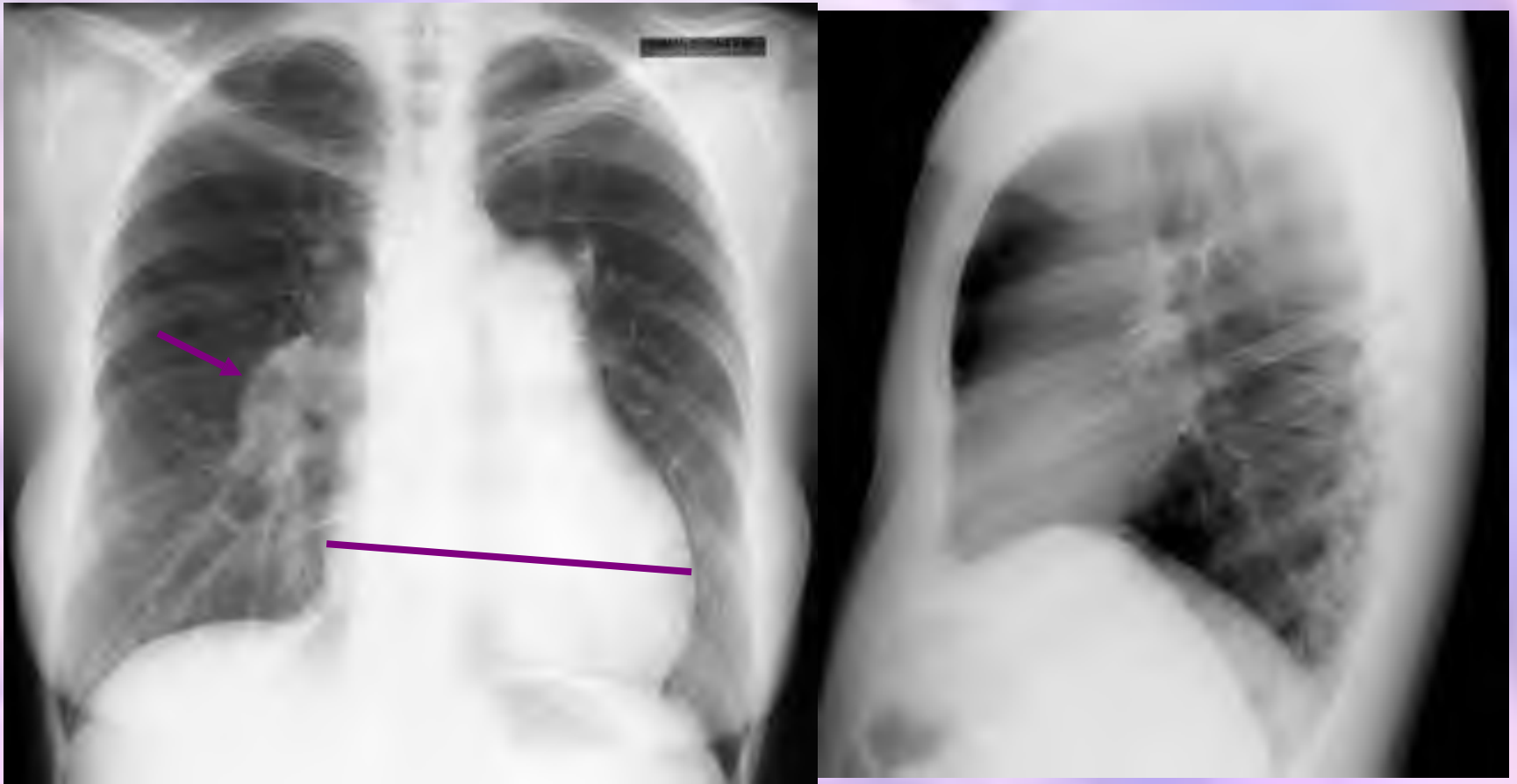




Widened Mediastinum: Aortic Dissection

Case 21





Pulmonary artery stenosis with cardiomegally likely secondary to stenosis.